

ORIGINAL RESEARCH ARTICLE

A CLINICAL STUDY ON TRACHOMA & ITS MANAGEMENT WITH HARITAKYADI EYE DROPS

NARAYAN BAVALATTI¹, MANJUSHA RAJGOPAL²

¹Associate Professor, Dept, of Shalakya, S.D.M College of Ayurveda Kuthpady, Udupi - Karnataka.

² Associate Professor, Dept, of Shalakya, IPGTRA, Jamnagar

Corresponding author email address: eyenimi@gmail.com

Access this article online :www.jahm.in

Published by Atreya Ayurveda Publications, Ilkal-587125 (India) All rights reserved.

Received on: 24/08/2013, Revised on: 30/08/2013, Accepted on: 10/09/2013

Abstract

Background: pothaki is one amongst the diseases of lid having multiple follicles resembling red mustard seeds or white mustard seeds, associated with itching, discharge, heaviness in lids etc. Its clinical features closely resemble the trachoma. Trachoma is a specific communicable keratoconjunctivitis usually of chronic in nature caused by the Chlamydia trachomatis, characterized by formation of follicles, papillary hyperplasia and pannus etc.

Aims and objectives: To evaluate the local effect of the haritakyadi eye drops on sign & symptoms and to compare the effect of trial drug and ofloxacin eye drop on the clinical features of trachoma

Methods and materials: The present clinical study was done on 118 patients of trachoma. A haritakyadi eye drop was instilled in group- A, ofloxacin in group - B as a standard control. After enrollment of the patients in the study, vital signs and symptoms of pothaki -trachoma were studied before and after the treatment. Amongst the registered patients 52 patients completed the course of treatment in each group

Results: In group – A, 36.53% patients were got marked improvement and 63.46% patients were moderately improved where as in group - B 59.61% patients were got marked improvement, and 40.38% patients were moderately improved.

Conclusion: The haritakyadi eye drop has not showed any side effects as observed through the course of treatment which indicates that the drug is safe in the management of trachoma

Key words: Pothaki, trachoma, haritakyadi eye drops.

Introduction

Trachoma is both an ancient and a stubborn disease; slow to blind, and obviously hard to “cure” in a public health context. All through human history, in times of peace as in times of war, it has taken a steady toll of human sight. Against this persistent affliction, some of the best minds in public health ophthalmology have been forging increasingly effective weapons to control and eliminate blinding trachoma¹

The diseases of eye lids (vartma) manifesting mainly due to the vitiation of rakta and mamsa dathus². pothaki is one amongst the diseases, having multiple pitikas (follicles) resembling red mustard seeds or white mustard seeds originate in the vartma due to vitiation of kapha dosha mainly, associated with discharge, itching, heaviness in lids and pain in the eye lid. It is the kapha predominant lekhana sadhya vyadhi.³⁻⁵. On the basis of clinical features of pothaki is equated with Trachoma by most of the scholars.

Trachoma is the leading cause of infectious blindness worldwide⁶ and is caused by ocular infection with the intracellular bacterium Chlamydia trachomatis⁷. Episodes of infection usually begin in childhood, while blindness from corneal scarring occurs after repeated infection, scarring of the

eyelids and distortion of the eyelashes, associated trauma and secondary bacterial infection⁸. Though exact data is not available but it is a fact that after the advent of Sulphonamides and quinolone group of antibacterial drugs the incidence, severity of Trachoma has come down but still it is not completely eradicated. Trachoma is responsible for the 15 – 20% of the world blindness; 500 million individuals are affected around the World and 150 million individuals with active trachoma⁹.

Antibiotics have played a key role in trachoma control efforts since the late 1930s¹⁰. However, sulfonamides proved to be too toxic to be used in mass treatment campaigns and tetracycline cannot be given systemically to children. The impact of topical tetracycline was limited, presumably (at least in part) because compliance was poor with the prolonged courses needed to cure infection¹¹.

According to a survey done Narayan. B and Manjusha. R 2005-07 at I.P.G.T and R.A Gujarat ayurveda university –Jamnagar, total number of screened patients from January 2006-June 2006 were 1210, among them 436 i.e. 36.03% patients were suffering from trachoma it indicates the virulence of trachoma organism in that particular area¹².

In ayurvedic classics, acharyas have explained various treatment protocols for the management of trachoma. The treatment may be local or systemic. e.g. lekhana karma¹³ anjana , ashchyotana or the oral administration of medicine for maintaining equilibrium of doshas. Hence, it is planned to carry out a study on Trachoma with aim to search better ayurvedic formulation in eye drops form to work as alternative to modern ophthalmic preparation. The present formulation selected for the research work is an anabhota yoga which contains triphala, shigru, lashuna, patola and daruharidra. Maximum drugs of the formulations were having lagu, ruksha guna, tikta, kashaya rasa, ushna virya along the with Antibacterial, Antiviral, Antitrachoma etc properties¹⁴⁻¹⁹. The eye drops were prepared by distillation process and sterile 10 ml packing was done under aseptic condition. Packing was done under laminar air flow.

The study was taken with hypothesis that kapha shamana and lekhana properties can interfere directly to the kapha predominant pothaki and resolve the pathogenic condition by the lekhana karma and chakshushya karma, hence the patients may get the relief from the signs and symptoms of the trachoma. Ofoxacin is kept as a standard control in this study.

Aims and objectives:

1. To evaluate the local effect of the drug in sign and symptoms of trachoma.
2. To compare the effect of trial drug and standard control drug on the signs and symptoms of trachoma.

Materials and methods

Selection of patients: Patients of trachoma fulfilling the inclusion criteria attending O.P.D. of Shalakya I.P.G.T and R.A G.A.U Jamnagar. A detailed proforma was prepared incorporating ayurvedic and modern points of trachoma.

Drug Details:

Haritakyadi eye drop is a anubuta yoga used for treating many eye disorders. It contains the haritaki (*Terminalia chebula Retz.*), bibhitaki (*Terminalia bellerica Roxb*), amalaki (*Phyllanthus emblica*), daruharidra (*Barberis aristata DC*), patola (*Trichosanthes dioica Roxb*), shigru (*Moringa oleifera Lam*), surasa (*Ocimum sanctum Linn*) and lashuna (*Allium sativum Linn*).

All the ingredients were made into yavakuta churna and taken in equal quantity & to this ten times of water was added. This mixture was kept for twelve hours after this boiled at 40 C.

When 60% of water got evaporated the boiling process was stopped. The distillate was collected in sterile jar. The procedure of packing in brief is as given below-

- ❖ Filtration by 2.0 microns glass filter followed by 0.2 microns nylon filter.
- ❖ Filtered solution was filled in sterile plastic bottles under Laminar Air Flow in aseptic conditions.
- ❖ Plugging and capping was also done in aseptic area.

Thus obtained distillate was passed into different microbial filter papers and pressure vessels ultimately obtained product was packed into 10ml sterile bottle.

Diagnostic criteria:

Diagnosis is based on the clinical feature and examination under slit lamp for tracomatous changes in conjunctiva and cornea.

Sampling technique: Simple random sampling method.

Inclusion criteria:

Patients presenting with classical features of trachoma confirmed on slit lamp examination were selected for study

Exclusion criteria:

- Patients operated for ocular disorders.
- Patients taking medications for systemic diseases.
- Known patient of allergic conjunctivitis were excluded from the study.

Ethical clearance:

The study was cleared by the ethical committee of the Institute. Written consent was taken from each patient willing to participate before the starting of the treatment. Those patients who were unable to read or write, consent of their relatives was taken. Patients were free to withdraw their name from the study at any time without giving any reason.

Investigations

1. Routine hematological examination
2. Urine analysis
3. S. cholesterol and blood sugar examination

Assessment of Therapy:

An assessment was made on change in clinical feature before and after treatment. The scoring was given to each clinical feature ranging from 0 – 3. No clinical feature – 0, mild- 01, moderate – 02 and severe – 03. The overall effect of therapy was assessed - Cured: 100% relief of the complaints and no recurrence during the follow up, Markedly improved - 75% and less than 100% relief in the complaint, Moderately improved-50% and less than 75% relief in the complaint, Mild improved - 25% and less than 50% relief in the complaint and unchanged 0 – less than 25% relief in the complaint.

Statistical analysis:

The obtained data on the basis of observations were subjected to statistical analysis in terms of mean, standard deviation, standard error and 't' test were conceded at the level of $P < 0.001$ as highly significant, $p < 0.05$ or $p < 0.01$ as significant, and or $p > 0.01$ as insignificant.

Intervention:

Drug delivery and duration:

Group A - Patients belonging to this group were administered with haritakyadi eye drops.

Dose 1 drop in each Eye 3 times a day for 2 months

Group B – patients belonging to this group were administered with ofloxacin eye drops.

Dose 1 drop in each Eye 3 times per day for 2 months

Every patient was assessed after the completion of the course of treatment

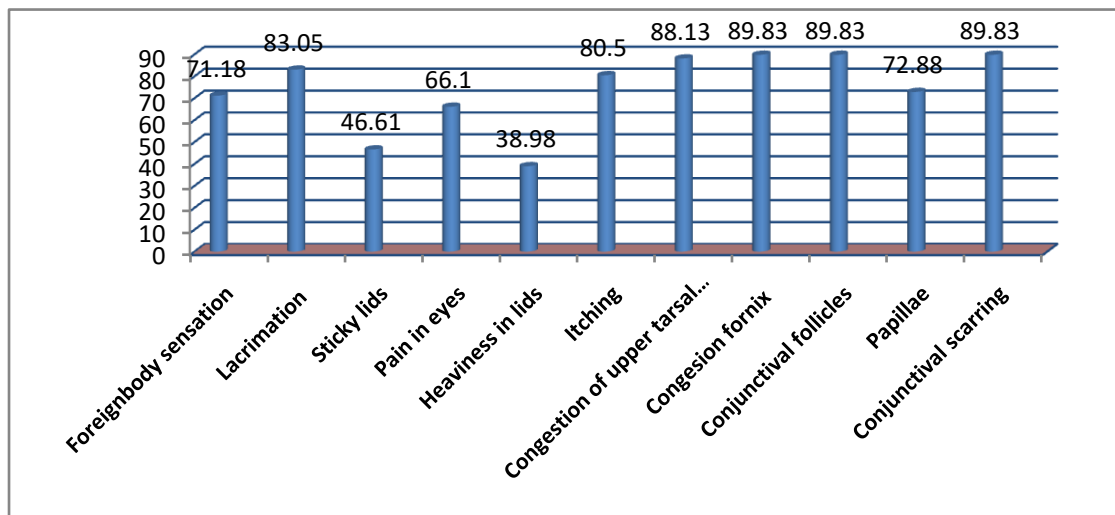
The study was conducted on 118 diagnosed cases of pothaki-Trachoma. Total 62 patients were registered in haritakyadi eye drops i.e. group A, amongst them 52 patients have completed the course of treatment and 10 patients discontinued. In ofloxacin group i.e. Group B; 56 patients were registered amongst them 52 patients completed the course of treatment and 04 patients discontinued during course of treatment.

General observations

*S. E M. CI – Socio economic status middle class

Some general observations of etiology in patients of trachoma

Clinical features of patients of trachoma



Results :

A

naly sis

after the administration of haritakyadi eye drops 75% relief was found in foreign body sensation, 80% relief in lacrimation, 95.45% relief was found in mucoid discharge, 64.28% relief was found in blurring of vision, 84.09% of relief was found in Pain in eyes, 66.66% relief was found in heaviness in lids, 75.32% relief was found in itching, 79.48% relief was found in stickness of lid, 78.16% relief was found in congestion of tarsal conjunctiva, 74.72% relief was found in congestion of fornix, 78.40% relief was found in follicles, 91.30% relief was found in papillae and 3.33% relief was found in scarring.(See Table No 1)

Table – 1. Total effect of therapy in Group –A

Features	BT	AT	Percent of relief	SD	SE	t	P
Foreign body	1.95	0.48	75	0.69	0.10	14.17	<0.001

sensation							
Lacrimation	1.66	0.33	80	0.63	0.09	14.65	<0.001
Mucoid discharge	1.22	0.05	95.45	0.51	0.12	9.62	<0.001
Blurring of vision	1.4	0.5	64.28	0.56	0.17	5.01	<0.001
Pain in eyes	1.18	0.18	84.09	0.40	0.06	14.89	<0.001
Heaviness in lids	1.32	0.44	66.66	0.43	0.08	10.00	<0.001
Itching	1.71	0.42	75.32	0.72	0.10	11.89	<0.001
Mucopurulent discharge	1.5	0.5	66.66	00	00	00	>0.01
Stickiness of lids	1.44	0.29	79.48	0.45	0.08	13.08	<0.001
Congestion of Tr.conjunctiva	1.70	0.37	78.16	0.55	0.07	17.19	<0.001
Congestion of fornix	1.75	0.44	74.72	0.50	0.07	18.62	<0.001
Follicles	1.69	0.36	78.40	0.61	0.08	15.49	<0.001
Papillae	1.02	0.08	91.30	0.25226	0.03	24.81	<0.001
Scarring	1.15	1.11	3.33	0.19	0.026	1.42	>0.01
Panus	1	0	100	00	00	00	>0.01

Analysis after the administration of ofloxacin eye drops 73.43% relief was found in foreign body sensation, 78.87% relief was found in lacrimation, 100% relief was found in blurring of vision, 81.30% of relief was found in Pain in eyes, 81.82% relief was found in heaviness in lids, 78% relief was found in itching, 91.89% relief was found in stickiness of lid, 83.28% relief was found in congestion of tarsal conjunctiva, 84.39% relief was found in congestion of fornix, 74.25% relief was found in follicles, 90.59% relief was found in papillae and 3.37% relief was found in scarring. (See Table No 2)

Table – 2. Total effect of therapy in Group –B

Features	BT	AT	Percent of relief	SD	SE	t	P
----------	----	----	-------------------	----	----	---	---

Foreign body sensation	1.72	0.45	73.43	0.65	0.10	12.16	<0.001
Lacrimation	1.44	0.3	78.87	0.45	0.06	17.70	<0.001
Mucoid discharge	1.21	0.15	86.95	0.40	0.09	11.63	<0.001
Blurring of vision	1.5	00	100	00	00	00	---
Pain in eyes	1.2	0.22	81.30	0.53	0.08	11.77	<0.001
Heaviness in lids	1.15	0.2	82.81	0.51	0.11	8.55	<0.001
Itching	1.66	0.35	78	0.51	0.07	17.95	<0.001
Stickiness of lid	1.42	0.11	91.89	0.47	0.08	14.70	<0.001
Congesion of Tr.conjunctiva	1.65	0.28	83.28	0.59	0.08	16.85	<0.001
Congesion of fornics	1.71	0.28	84.39	0.63	0.08	16.66	<0.001
Follicles	1.59	0.42	74.25	0.67	0.09	12.84	<0.001
Papillae	1.07	0.12	90.59	0.22	0.03	27.95	<0.001
Scarring	1.09	1.05	3.37	0.19	0.02	1.40	>0.05
Panus	01	00	100	00	00	00	---

Overall effect of therapy:

Discussion:

The discussion is the supreme part of a clinical study so that one can understand certain hidden facts of the problem and a definite conclusion can be drawn by the study.

trachoma is one of the preventable blindness. W.H.O lunched a programme vision for all by 2020 with implementing SAFE campigion²⁰.

Trachoma and associated infections are still the most important causes of preventable blindness in the world. Trachoma is responsible for the 15 – 20% of the world blindness; 500 million

individuals are affected around the World and 150 million individuals are with active trachoma²¹. Maximum number of patients attending the OPD of Shalakya Dept. presents with different stages of trachoma showing its virulence in Jamnagar population. Hence it was decided to conduct the study on patients attending the shalakya OPD to know the efficacy of haritakyadi eye drops an anubhota yoga used in hospital to treat eye disorders.

In the present study maximum number of patients i.e. 22.88% belonged to age group of 41-50 years. In the classics it was explained that children are main reservoir of infection²² where as in our observation maximum patients belonged to age group 41-50 years.

On considering the nature of occupation, it was found that maximum i.e. 30.50% patients were housewives; dhumanisevana is very common for the housewives as their routine work is generally to cook and clean the house which in turn is a risk factor of Trachoma.

Maximum i.e. 26.53% patients were having primary education, this especially recognized in relation to inadequate education. Here we can say that primary education is not sufficient to become aware about lot of contagious diseases hence probably primary educated patients were more affected²³.

The observation showed that 55.08% patients belonged to middle socio-economic class. In literature it is explained that economically poor communities are at greater risk of trachoma as their lifestyle is characterized by a deprived social status. Poor socio-economic status and unhygienic conditions play role in etio-pathogenesis of the disease and are the pre disposing factors²⁴⁻²⁵.

Probable mode of action of haritakyadi Eye drops:

The pathogenesis of trachoma which is available in Ayurvedic classics is insufficient for explaining the mechanism of drug action, still effort has been made hypothetically on the basis of inherent properties of the contents of the formulation.

The drugs were having pungent, bitter, astringent, sweet and sour taste; light, dry, sharp, oily and viscous properties. Katu rasa and katu vipaka is having hot, digestive, kapha pacifying properties. Shlesmopashoshana properties are possessed by tikta rasa. Kashaya rasa shows its shoshana, more particularly kleda shoshana and shleshma prashamana properties. The drugs having madhura vipaka possess rasayana, cakshushya, jivaniya, balya properties. Because of its rasayana action the substrate dhatus, vitiated dhatu as well as other structures of the eye may be nourished. Thus helps for improving the functional capacity of the eye and it also helps to decrease the various symptoms. ushna virya has lekhana, chedaniya, shodhana, rasayana, chakshushya and kaphanashaka effect which helps to correct the vitiated kapha which is a predominant pothaki and simultaneously sheeta virya helps in maintaining the cold nature of drishti.

Tikta rasa shows its chedana property; katu rasa is tikshna and possesses marga vivarana action. Because of these inherent properties of the drugs, after getting absorbed it may scrap away the vitiated kapha, and meda already lodged in the eye Lids.

The shuddha srotasa (opened channel) allows the proper movement of doshas. This Pitta performs its normal functions of visual perception which were previously experiencing hindrance due to vitiated kapha. The specific activity like kaphahara and pittshamaka may overall attempt to enhance the qualities of tarpaka kapha and alocaka pitta by elevating the disturbance related to them. On the other hand the haritakyadi eye drops when administered topically the molecules present in it may bind to the proteins of the pre corneal tear film and then it remain in the cul-de-sac, after reaching highest

concentration it may enters to the epithelium of the conjunctiva and the cornea by diffusion process where the drug is needed to arrest the pathological process. The drugs used in haritakyadi eye drops have the antibacterial, antiviral and anti trachoma activity, as it enters into the cells of the epithelium of conjunctiva and cornea, it may acts on the organisms and resolves the pathogenesis. Hence patients get relief in the signs and symptoms pothaki-Trachoma.

Conclusion:

The haritakyadi eye drop has not showed any side effects as observed through the course of treatment which indicates that the drug is safe in the management of trachoma. haritakyadi eye drops showed more improvement on the clinical features like lacrimation, stickiness of lid, Itching, Follicles and Papillae as compared with ofloxacin. The ofloxacin showed more improvement on the clinical features like blurring of vision, heaviness in lids, itching, stickiness of lids, congestion of tarsal conjunctiva and papillae.

Reference

1. Silvio p. Mariotti, Ramachandra parrajasegaram et al. Trachoma: looking forward to global elimination of trachoma By 2020 (get 2020), Am. J. Trop. Med. Hyg., 69(Suppl 5), 2003, p.33
2. Vaidya Yadunandana Upadhyaya, Vidyotini Hindi Commenatry , Astangahrudayam of Vagbhata, Uttarasthana, Chapter 8, verse 1, 14th edition, Choukhamba Sanskrit Bhavana , Varanasi, 2003, p.479
3. Kaviraja Ambikadatta Shastri, editor, Ayurveda tatwasandeeepika of Sushruta Samhita, Uttarantra, Chapter 3, verse 11, 8th edition, Varanasi, Chaukhamba Sanskrit Sansthana, 1993, p.16
4. Kaviraja Ambikadatta Shastri, editor, Ayurvedar tatwasandeeepika of Sushruta Samhita, Uttarantra, Chapter 13, verse 14, 8th edition, Varanasi, Chaukhamba Sanskrit Sansthana, 1993, p.51
5. Vaidya Laxmipathi shastri, Yogartnakar with vidyotini hindi commentary, edited , Bhisagratna Brahmashankar shastri, Uttarardha, netrogadhikara, vartmaroga, verse 77, Varanasi, 7th edition, Choukhamba Sansthan, 1999, p.350
6. Resnikoff S, Pascolini D, et. al. Global data on visual impairment in the year 2002. Bull World Health Organ 82: 844–851, 2004.
7. David mabey, Anthony w. Solomon, Application of molecular tools in the control of blinding trachoma, Am. J. Trop. Med. Hyg., 69 (Suppl 5), 2003, p.11
8. Robin Bailey & Tom Lietman et. al The SAFE strategy for the elimination of trachoma by 2020: will it work? Bulletin of the World Health Organization, 2001, 79 (3) , Page 223
9. Khurna A. K . Comprehensive ophthalmology, 3r editin, New delhi, New Age International (P) Ltd, 2007, p.62, 63
10. Freyche MJ, Antibiotics and sulfonamides in the treatment of trachoma. Bull World Health Organ 1950, 2: 523–544.
11. David mabey, Anthony w. Solomon, Application of molecular tools in the control of blinding trachoma, Am. J. Trop. Med. Hyg., 69 (Suppl 5), 2003, p.11
12. Narayan B, Manjusha R, A clinical study on trachoma, shalakyia Dept, IPGT & RA , G.A.U Jamnagar, Gujarat, 2007 (Thesis)
13. Kaviraja Ambikadatta Shastri, editot, Ayurvedar tatwasandeeepika of Sushruta Samhita, Uttarantra, Chapter 13, verse 14, 14th edition, Varanasi, Chaukhamba Sanskrit Sansthana, 2001, p.51
14. Chunekar K .C, Bhavaprakasha Nighantu, reprint, Varanasi, Chaukhamba Bharati Academy, 2006. p.5, 9, 10, 20, 21, 118, 119, 122, 131, 339, 686.
15. Sharma P.V, Dravyaguna vignana, Vol II, reprint, Varanasi Chaukhamba Bharati Academy, 2003 p.72, 111, 758, 239, 753, 513, 537, 617, 266, 267, 403
16. Bapalal G. Vaidya, Nighantu Adarsha, Vol I, repring, Varanasi, Chaukhamba Bharati Academy, 2007, p. 576, 550, 401, 618, 345

17. P.C. Sharma, M.B. Yelne, T.J. Dennis, Database on medicinal plants used in ayurveda, New delhi, CCRAS, 2001,Vol I – p.120, 431
18. P.C. Sharma, M.B. Yelne, T.J. Dennis, Database on medicinal plants used in ayurveda, New delhi, CCRAS, 2001,Vol II p.500
19. P.C. Sharma, M.B. Yelne, T.J. Dennis, Database on medicinal plants used in ayurveda, New delhi, CCRAS, 2001, volume III, p.284, 160, 14
20. Robin Bailey, Tom Lietman et. al The SAFE strategy for the elimination of trachoma by 2020: will it work? Bulletin of the World Health Organization, 2001, 79 (3) p.223
21. Khurna A. K . Comprehensive ophthalmology, 3r editin, New delhi, New Age International (P) Ltd, 2007, p.62
22. W.H.O, Achieving community support for Trachoma control, A guide for district health workers- 1995 p.3
23. Teaching series No – 7, published 2006, International Centre for Eye Health, London School of Hygiene & Tropical Medicine, Keppel Street, London, WC1E 7HT, UK, 1999.
24. Park K, Parks text book of preventive and social medicine, 15th ed, Jabalpur, Banarasi bhanot publishers,1997 p.630
25. W.H.O, Achieving community support for Trachoma control, A guide for district health workers- 1995 p.2

Cite this article as: Narayan Bavalatti, Manjusha Rajgopal, A clinical study on trachoma & its management with haritakyadi eye drops, Journal of Ayurveda and Holistic Medicine; 2013; 1(6):----

Source of support: Nil, Conflict of interest: None Declared.