



A CASE STUDY ON AYURVEDIC MANAGEMENT OF DEVIATED NASAL SEPTUM

SHEETAL SURESH SONWANE^{1*}, KAVITA FADNAVIS²

^{1*}PG Scholar, ²PG Guide and Associate Professor, Department of Kaumarbhritya, CSMSS Ayurved college, Chhatrapati Sambhajanagar, Maharashtra, India

Corresponding Author Email: sheetal2796@gmail.com Access this article online: <https://jahm.co.in>

Published by Atreya Ayurveda Publications under the license CC-by-NC-SA 4.0

Submitted on- 21-05-24

Date of revision- 25-05-24

Accepted on-28-05-24

ABSTRACT:

Deviated nasal septum (DNS) is a relatively prevalent disorder that can cause obstructive sleep apnea, migraine, sinusitis, epistaxis, and nasal blockage in moderate to severe cases. Patients suffering from DNS switch to alternate therapies due to the return of symptoms. *Peenasam* or *Nasanaah* resembles the clinical signs of DNS. Our study's objective was to ascertain whether traditional *Viddha karma* can serve as an additional therapeutic option in case of DNS by lowering the patients' current symptoms, and medication dependence without the need for surgery for relief of symptoms. *Viddha Karma* has been used to cure adults for symptoms brought on by DNS, sinusitis, and hypertrophied turbinates. This article describes a 16-year-old male patient who had three *Viddha* sessions over the course of a week on alternate days for his Hypertrophied turbinates and Deviated nasal septum. The Snot-22 questionnaire and lab investigations showed improvement. The functional outcome was achieved in the patient along with *Nasya* and some Ayurvedic medicines. *Viddha karma*, along with *Nasya* and Ayurvedic medicines is highly effective in treating symptoms.

Keywords: Chronic sinusitis, Deviated nasal septum, *Nasanaah*, *Peenasam*, *Viddha*, SNOT-22 (Sino Nasal Outcome Test-22)

INTRODUCTION:

In the pediatric age group, nasal obstruction is a highly prevalent and problematic issue. Turbinate hypertrophy and deviated nasal septum are mostly responsible. Nasal allergies, vasomotor rhinitis, and nasal masses, polyps are other etiological variables that may be implicated. The inferior turbinates are mostly in charge of humidification, heating, filtering, and direction of airflow that enters the nose [1]. Turbinate hypertrophy can result from allergies, exposure to environmental irritants, or chronic sinusitis and also be caused by deformities in the nasal septum and thickening of soft tissues. Numerous antihistamines, decongestants, and topical and systemic corticosteroids are part of the medical therapy. These medications can only treat the symptoms; they cannot treat the underlying cause of the illness. Additionally, they may cause adverse effects like bleeding, crusting, dryness, and sleepiness [2]. The treatment of nasal blockage has used a variety of surgical techniques, including submucosal diathermy, laser therapy, linear cautery, inferior turbinate cutting, and turbinate cryotherapy. While they all seem to work in the short term, they don't offer any long-term advantages.[3] Two of the more recent methods include radiofrequency ablation and micro debridement of the turbinates; however, there are currently no long-term studies on their efficacy.[4] Consequently, a wide variety of surgical procedures have been performed to alleviate persistent nasal obstruction resulting from

hypertrophied turbinates; however, the results have not always been satisfactory. A deviated septum can cause sinus infections, sleep apnea, snoring, frequent sneezing, face pain, nosebleeds, mouth breathing, breathing difficulties, a slight to severe loss of smell, and reduced lung volumes[5,6]. There are numerous epidemiological studies done over the last decades on the prevalence of DNS in human beings from the newborn period to the adult age group. The prevalence varies from 0.93% to 55% [7].

Ayurvedic texts state that *Nasapratinaha* (DNS), a combination of the vitiated *Vata* and *Kapha* doshas, obstructs inspired air and causes nasal blockage. Based on the traditional symptoms, it can be classified as a hypertrophied turbinate nasal obstructive lesion, which entails swelling of the submucosa and, in rare cases, the bone itself.[8] *Ayurvedic* treatments such as *Nasya*, *Vidhha karma*, and *Ayurvedic* medications are very effective in managing *Urdhwajatrugat vyadhi*, and long-term outcomes can be attained with proper lifestyle choices. Hence here an attempt is made to add light on the effects of *Viddhakarma* in DNS.

CASE REPORT

The 16-year-old male child was brought by their parents in OPD with complaints of frequent cold, blocked nostrils, post-mucoid discharge, difficulty in sleeping, and oral breathing on and off for the last 9 months.

Clinical examination:

General condition- Good

Pulse- 82/min.

Respiratory System- Air Entry Bilaterally Equal

Cardiovascular System- S1 S2 Normal

Ashtavidha Parikshana

Nadi- Vatapradhana Pitta

Mutra- Samyak Pravritti

Mala- Samyak Pravritti

Jivha- Saama

Shabda- Prakrit (normal)

Sparsha- Samashitoshna,

Druk-Prakrit

Akriti- Madhyama

Prakriti Parikshana- Vatapitta Pradhana

Koshtha- Madhyam

Local Examination-

The nose was normal in size and form. Externally, there were no edema or abnormalities.

An examination of the Thudicum's nasal speculum showed Nasal cavity was swollen and irritated. No possible areas of bleeding, no foreign body in the nasal cavity, Septal perforation, nasal polyp, and septal spur absent. Thick nasal discharge, congested nasal mucosa, and bilateral inferior turbinate hypertrophy were noted.

Past history

The patient had taken medical management which included a variety of antihistamines, decongestants, and topical and systemic corticosteroids for 9 months but was of no use

as After discontinuation of medication recurrence of the *Nasanaha* was observed.

CT-PNS (Fig no.1) was done by patient 6 months ago showed Soft tissue mucosal thickening in frontal and anterior ethmoid sinus-sinusitis.

Bilateral inferior turbinate hypertrophy with soft tissue mucosal thickening causing partial nasal cavity obliteration rhinitis. Mild Deviated nasal septum towards the left side.

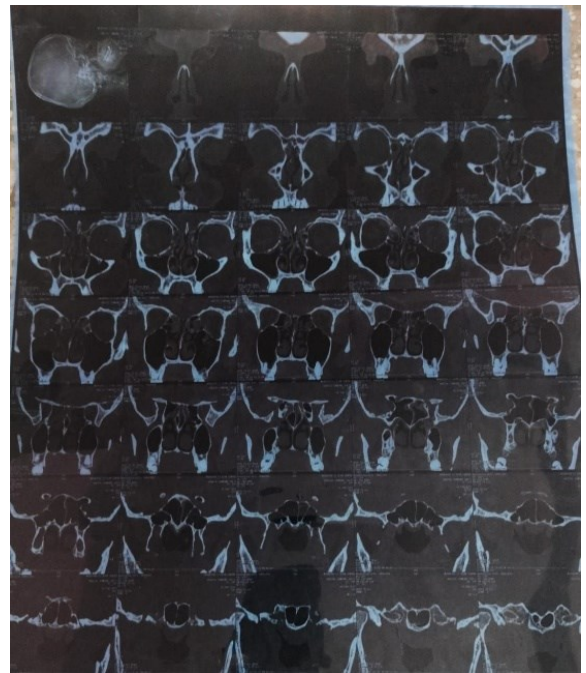


Fig no.1 CT -PNS

Assessment Criteria: SNOT-22[9] questionnaire, CBC, ESR and serum IgE Levels were checked.

Treatment:

Viddha karma points: Nasaagra (tip of nose) [10,11] and Upanasika(nasal flares at start of depression) [10,11] (Fig. 2 and 3 respectively)

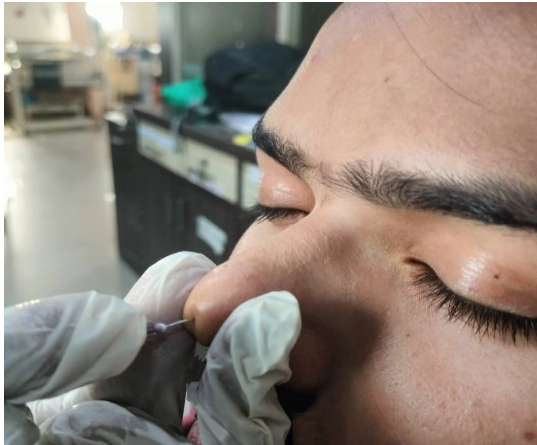

Fig no. 2 Nasagra

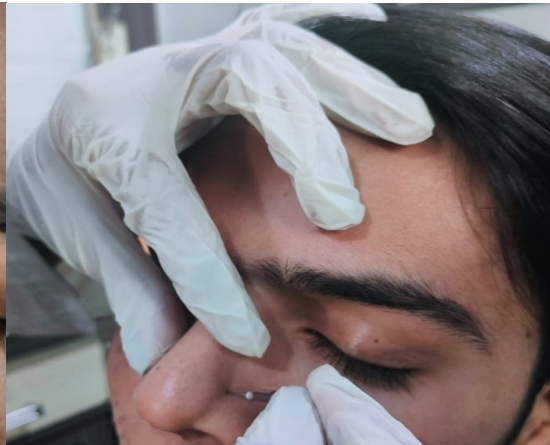

Fig no. 3 Upanasika

Viddhakarma standard operating procedure (sop)

Poorva karma (pre-procedure):

1. *Viddhakarma* should be carried out in clean and ventilated room with sufficient light.
2. *Vaidya* should be wearing sterile gloves, mask and a surgical cap.
3. Tools - disposable needle no. 26 1 & ½.

Pradhan karma:

1. Selected *Viddha* points.
2. Prick the disposable needle perpendicular to the *Viddha* point.
3. During *Viddhakarma* process if disposable needle is filled with blood, then it should be replaced with another one.
4. Keep the disposable needle pricked for 5-6 sec.

5. The vitiated blood has low coagulant tendency to flow freely. Once the impure blood drains out, the fresh blood automatically clots. So, blood should be allowed to flow freely after *Viddhakarma* since it drains out vitiated dosha. Usually about 0.2 – 0.5 ml blood drains out from *Viddha* point.

Paschat karma

1. Blood oozed out from the pricked site was wiped with cotton.
2. The needle used for *Viddhakarma* was disposed of.

Duration of study – 3 months

- Follow up Session – 0th, 2nd, 4th, 6th, 8th, 10th, 12th, 14th, 16th, 18th, 20th, 22nd, 24th, 26th, 28th, 30th day in 1st month, later every week once for next 8 weeks.

Table no.1: Intervention

	Chikitsa :	METHOD	DURATION
Shodhan chikitsa	Nasya	1. <i>Sthanik Snehan</i> 2. <i>Swedan</i> 3. <i>Anutailam nasya</i> 0.3ml in each nostrils. 4. <i>Gandush</i> with luke warm water	Once daily in the morning
Shaman chikitsa		1. Tab. Allerkhand contents:	For 15 days.

	<p><i>Ela (Elettaria cardamomum),</i> <i>Pippali (Piper longum),</i> <i>Vidang (Embelia ribes),Haridra (Curcuma longa),</i> <i>Tulsi(Operculina turpethum),Haritaki (Terminalia chebula),Aamalaki (Emblica officinalis), Vibhitaki (Terminalia bellerica), Ardrak (Zingiber officinalis),Marich (Piper nigrum) ,Musta (Cyperus rotundus),Gokshur (Tribulus terrestris) ,Tamal (Cinnamomum tamala),Nagkeshar (Mesua ferrea),Twak (Cinnamomum zeylanicum) 1 tab OD</i></p> <p>2.Tab. Sukshma trifala</p> <p><i>Contents:Haritaki (Terminalia chebula),Aamalaki (Emblica officinalis), Vibhitaki (Terminalia bellerica), Kajjali (Mercury sulphide) 1 tab OD</i></p>	
--	--	--

Patient advised to avoid ice-creams, cold beverages, extreme hot and cold food, sleeping on time and lifestyle modifications.

Observations:

Table no.2: BT and AT Assessment

SNOT 22 QUESTIONNAIRE	Before Treatment	Just after viddha	After completion of treatment
1. Need to blow nose	3	2	0
2. Sneezing	2	1	0
3. Runny nose	3	1	0
4. Cough	1	0	0
5. Post nasal discharge (dripping at the back of your nose)	3	1	0
6. Thick nasal discharge	3	1	0
7. Ear fullness	0	0	0
8. Dizziness	0	0	0
9. Ear pain/pressure	0	0	0
10. Facial pain/pressure	0	0	0
11. Nasal blockage	5	2	1
12. Waking up at night	4	1	1

13. Lack of a good night's sleep	4	1	0
14. Waking up tired	3	1	0
15. Fatigue during the day	2	0	0
16. Reduced productivity	2	0	0
17. Reduced concentration	1	0	0
18. Frustrated/restless/irritable	2	1	0
19. Sad	0	0	0
20. Embarrassed	3	1	0
21. Sense of taste/smell	1	0	0
22. Blockage/congestion of nose	3	0	0
TOTAL SNOT 22 SCORE	45	13	2

Gradation of above questionnaire are as follows:

No problem -0

Very mild problem- 1

Mild or slight problem – 2

Moderate problem -3

Severe problem -4

Problem as bad as it can be -5

(SNOT- 22 total score 8-20 represents mild, > 20 to 50 represents moderate and > 50 represents severe condition.)

Table no. 3: Lab investigations

LAB INVESTIGATIONS	Before treatment	After treatment (after 1month)
ESR	50mm/hr	12mm/hr
SERUM IgE	200IU/ml	70IU/ml

CBC was found to be normal.

DISCUSSION:

Viddhakarma is a sterile procedure of puncturing or piercing selected points with special hollow needles called as "*Viddha karma shalaka*". *Nasaagra* (tip of the nose) is supplied by the External nasal Nerve[11] and Lateral nasal artery and vein. *Upanasika* (nasal flares) has to have an Infraorbital branch of the Trigeminal nerve zygomatic branch of the facial nerve supply an infraorbital branch of the maxillary artery, Lateral nasal branch of a facial artery supplying it. Hence reducing the symptoms of the patient by stimulating and acting on the above vessels. Just after *Viddha patient experienced* a feeling of lightness of the head and clearance of the airway, Mitigation of suffering by Subsiding of the severity of nasal obstruction, and Cheerfulness of mind.

Snehana/Mukhabhyanga causes *Mriduta* of *Doshas* and according to modern science massage to a specified area causes increased blood circulation.[12] *Swedana Karma* causes *Vilayana*(liquefaction) of accumulated *Doshas* (mucous).[12] In *Nasya Karma*, the *Taila* instilled in the nasal cavity moves to the olfactory epithelium and Olfactory Bulb which proceed through the Cribriform Plate, Anterior Cranial fossa, and medial or lateral area of the cerebral cortex. The chemical impulse, which is generated by *Nasya* finally converts into a neuronal impulse and influences on cerebral cortex area thereby producing a stimulatory effect resulting in the evacuation of *Doshas*.[13]The *Nasya Dravya* also nourishes and rejuvenates the olfactory nerve and helps in its proper function. From *the Ayurvedic* view, drug administration done through the nose reaches the *Shringataka Marma* and spreads throughout *Murdha, Netra, Shrotra, and Kantha* through their *Shiras (Shringataka Marmais a Sira Marma* and formed by the *Shiras of Nasa, Akshi, Jivha* and *Shrotra*).[14] There by eliminates the morbid *Doshas of Urdhwajatru Vyadhis* (diseases of the upper part of the body), expels them from the *Uttamanga* and helps in relieving the disorders.[15]

Tab . Allerkhand and Sukshmatrifala vati have *deepan, pachan, vata-kafashank, and tridoshar properties and anti-inflammatory action*, hence effective in reducing the hypertrophy of turbinates and nasal obstruction.

CONCLUSION:

In the current case study, the patient's *Nasanaah* significantly improved in terms of both clinical and analytical markers. There were no unanticipated side effects from therapy during treatment or the follow-up period. Thus, it can be concluded that *Viddha, Nasya and Ayurvedic, medicines* are very successful in treating DNS and turbinate hypertrophy; however, more research including a larger sample size will be necessary to confirm this influence in the pediatric age group as well as their response to this course of treatment.

DECLARATION OF PATIENT CONSENT:

The authors confirm that they have acquired a patient consent form, in which the patient or caregiver has granted permission for the publication of the case, including accompanying images and other clinical details, in the journal. The patient or caregiver acknowledges that their name and initials will not be disclosed, and sincere attempts will be undertaken to safeguard their identity. However, complete anonymity cannot be assured.

REFERENCES:

- 1.Kotrannavar VK, Angadi SS. Kshara application for turbinate hypertrophy. J Ayurveda Integr Med. 2013 Oct;4(4):241-4. doi: 10.4103/0975-9476.123722. PMID: 24459392; PMCID: PMC3891181.
- 2.Powell NB, Zonato AI, Weaver EM, Li K, Troell R, Riley RW, et al. Radiofrequency treatment of turbinate hypertrophy in subjects using continuous positive airway pressure: A randomized, double blind, placebo-controlled clinical pilot trial. Laryngoscope. 2001;111:1783–90. [PubMed] [Google Scholar]. Crusting

3. Warwick-Brown NP, Marks NJ. Turbinate surgery: How effective is it? A long-term assessment. *ORL J Otorhinolaryngol Relat Spec.* 1987;49:314–20. [PubMed] [Google Scholar]
4. Grymer LF, Illum P, Hilberg O. Septoplasty and compensatory inferior turbinate hypertrophy: A randomized study evaluated by acoustic rhinometry. *J Laryngol Otol.* 1993;107:413–7. [PubMed] [Google Scholar]
5. Willatt D. The evidence for reducing inferior turbinate's. *Rhinology.* 2009;47:227–36. [PubMed] [Google Scholar]
6. Mathai J. Inferior turbinectomy for nasal obstruction review of 75 cases. *Indian J Otolaryngol Head Neck Surg.* 2004;56:23–6. [PMC free article] [PubMed] [Google Scholar]
7. Šubarić M, Mladina R. Nasal septum deformities in children and adolescents: a cross sectional study of children from Zagreb, Croatia. *International journal of pediatric otorhinolaryngology.* 2002;63(1):41-8.
8. Scott-Brown . In: *Otolaryngology.* 6th ed. 9th Chapter. Mackay, Bull, editors. Oxford: Butterworth-heinemann; 1997. p. 10. [Google Scholar].
9. Plath M, Sand M, Cavaliere C, Plinkert PK, Baumann I, Zaoui K. Normative data for interpreting the SNOT-22. *Acta Otorhinolaryngol Ital.* 2023 Dec;43(6):390-399. doi: 10.14639/0392-100X-N2279. Epub 2023 Oct 10. PMID: 37814974; PMCID: PMC10773542.
10. Sushrut Samhita, Chaukhamba Prakashan, Sutrashtan Chapter 8
11. Viddhakarma and Agnikarma book. Dr R B Gogate Page number 36
12. Vipin Kumar. A Conceptual Study on Mode of Action of Nasya. *International Journal of Ayurveda and Pharma Research.* 2017; 5(7):100102.
13. Tarun Kumar Dwibedi, Gururaj N, Shashikala K, Veerayya R Hiremath. A Case Report of Shadbindu Taila Nasya and Trikatu Dhoomapana on Apeenasa - Atrophic Rhinitis . *International Journal of Ayurveda and Pharma Research.* 2019; 7(3): 55-58.
14. A.K. Pandey and S.K. Tripathi. Shalaky Tantra in Sushruta Samhitha- A literary review. *World Journal of Pharmaceutical Research,*2017; Vol 6, Issue 03
15. Mahesh Kumari Thakur, Anjali. Panchnidanatmak Study of Vataja Pratishyaya w.s.r Allergic Rhinitis. *Ayushdhara [Internet].* 2024Jan.5 [cited 2024May15];10(6):38-41.

CITE THIS ARTICLE AS

Sheetal Suresh Sonwane, Kavita Fadnavis. A Case study on Ayurvedic management of Deviated nasal septum. *J of Ayurveda and Hol Med (JAHM).* 2024;12(5):78-85

Conflict of interest: None

Source of support: None