



CASE REPORT

VARIATION IN THE DIVISION OF SCIATIC NERVE: A CASE REPORT

¹TANVI MAHAJAN, ²BHOSGIKAR ANUP, ³N.G.MULIMANI

¹ 2nd year P.G Scholar, ² Lecturer, ³ Professor & H.O.D Department of Rachana Shareera, NKJAMC & P.G Center, Bidar, Karnataka, India

Corresponding author email address: drramesh39@gmail.com

Access this article online: www.jahm.in

Published by Atreya Ayurveda Publications, Ilkal-587125 (India) All rights reserved.

Received on: 29/04/14, Revised on: 29/04/14, Accepted on: 29/04/14

SUMMARY

The sciatic nerve is the nerve of the posterior compartment of the thigh. It is the largest nerve of the body. Not only does it have the largest number of nerve fibers, but it also supplies a vast region. It controls hamstrings and all muscles of the lower limb below the knee. We are reporting a unilateral division of the sciatic nerve found in a 45 year old male cadaver. The division of sciatic nerve into tibial nerve and common peroneal nerve was found to be in the pelvic region instead at the upper angle of popliteal fossa. Incidence of this variation in general population needs to be investigated so as to create awareness among surgeons and anesthetists about the degree and extent of variation in sciatic nerve formation.

Key Words: Human cadaver, Posterior compartment of thigh, Pelvic cavity, Sciatic nerve, Tibial nerve, Common peroneal nerve.

INTRODUCTION -Sciatic nerve is the thickest nerve in the human body and the largest branch of the sacral plexus, which is directly accessible in the interval between the gluteus maximus and long head of biceps femoris. It is formed by ventral rami of L4, L5, S1, S2, and S3. It is typically 2 cm wide at its origin near the sacral plexus. It leaves the pelvis via the greater sciatic foramen below piriformis as a single nerve encompassed by a single epineural sheath and descends between the greater trochanter of femur and ischial tuberosity, along the back of

the thigh. The level of division is most frequently at the level of the upper angle of popliteal fossa into two large terminal branches named Tibial and Common peroneal nerve. The Tibial nerve is derived from the anterior divisions of the sacral plexus(L4, L5, S1–3). The Common fibular nerve (common peroneal nerve) is derived from the posterior divisions of the sacral plexus(L4, L5, S1, S2)^[1].

CASE REPORT - During the routine dissection class of the postgraduates in our N.K.J. Ayurvedic Medical College and P.G. Centre

Bidar, the division of the sciatic nerve within the pelvis was observed in right lower limb of 45 year old male cadaver. In this case, the sciatic nerve divides in the pelvis by giving two branches i.e Tibial and Common peroneal nerve in front of piriformis muscle. In gluteal region, the tibial nerve passed inferior to the piriformis muscle and common peroneal nerve runs through piriformis muscle.

Observation: Figure 1 shows the normal course of sciatic nerve in the gluteal region of left limb of the 45 year old male cadaver. Here the sciatic

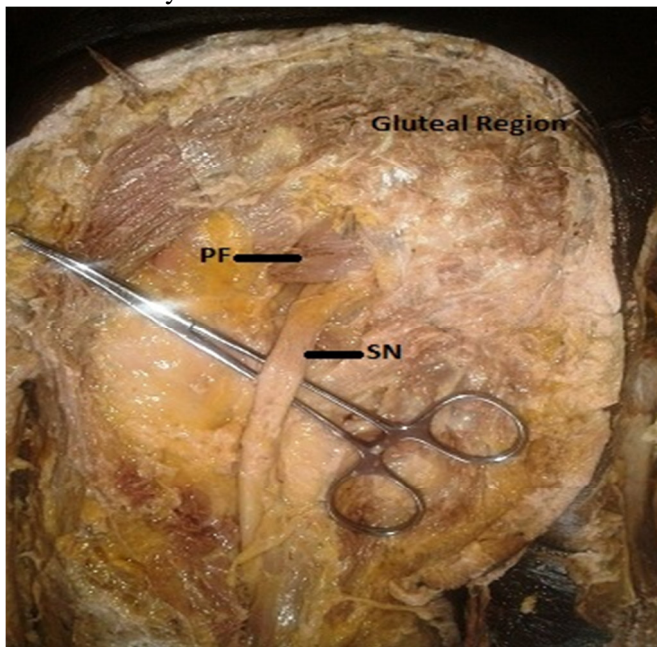


Fig 1. Showing normal course of Sciatic Nerve in gluteal region on left limb. [PF- Piriformis, SN- Sciatic Nerve]

DISCUSSION: Many variations during the course and distribution of sciatic nerve have been reported. The point of division of the sciatic nerve into its major components (tibial and common fibular) is very variable. The common site is at the junction of the middle and lower thirds of the thigh, near the apex of the popliteal fossa, but the division may occur at any

nerve pass below the piriformis muscle in gluteal region. The figure 2 shows the bifurcation of sciatic nerve on the right limb of the 45 year old male cadaver. In this case, the sciatic nerve divides in the pelvis by giving two branches i.e Tibial and Common peroneal nerve in front of piriformis muscle. In gluteal region, the tibial nerve passed inferior to the piriformis muscle and common peroneal nerve pierced the piriformis muscle. Both the nerves were normal in their size and course and gave out their respective other branches in normal way.

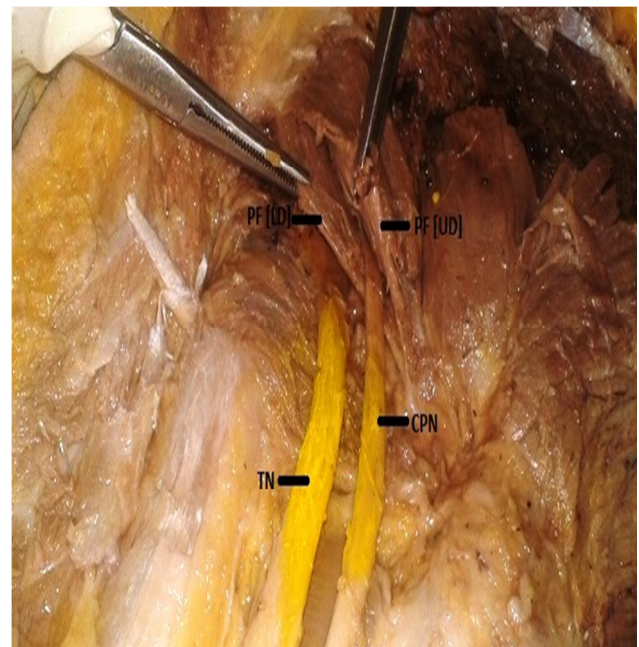


Fig.2 Showing variation in division of Sciatic Nerve in right limb of male cadaver.[PF-Piriformis,UD- Upper division, LD- Lower division, TN- Tibial Nerve, CPN- Common Peroneal Nerve.

level above this point, and rarely may occur below it.

During embryological development at the base of the limb bud, the nerves contributing to the lower limb form two plexuses (lumbar and sacral). Later, as the elements from each of these plexuses grow out into the limb, they are subdivided into dorsal and ventral components,

for the dorsal and ventral musculatures. The sciatic nerve is formed when the large dorsal component of the sacral plexus (common peroneal nerve) and the ventral component (tibial nerve) move downward close together. The two portions of the sciatic nerve develops separately in early embryonic stage and maintain their identity throughout their extension, although joined together to form a single nerve trunk by a common connective tissue sheath^[2]. Thus, during the development, the two components of sciatic nerve in the process of unification get wrapped around by a common connective tissue sheath. The level at which common connective tissue wrapping comes to a halt, branching of sciatic nerve into common peroneal and tibial components is seen.

Hence, based on their previously mentioned developmental formation, it is possible that the common peroneal and the tibial divisions of the sciatic nerve separate from each other at different levels from their origins - within pelvis, in the gluteal region, the posterior compartment of the thigh or at the apex of popliteal fossa. Various studies have been reported on the level of sciatic nerve division into tibial and common peroneal nerve.

In recent studies it is revealed that, in 2.5% - 12.2% cases common peroneal nerve pierced piriformis & tibial nerve passed below this muscle. Common peroneal nerve & tibial nerve passed above and below the piriformis respectively in 0.5% to 4% cases. Unsplit sciatic nerve piercing the piriformis is found in 1% case only^{[3][4][5]}. In the present study the common peroneal nerve passing through the piriformis muscle which is a rare one, has been noticed.

REFERENCES:

1. Susan Standring, Edited Gray's Anatomy, 40th edition, Churchill Livingstone, Elsevier; 2008; p.1384.
2. Babinski MA, Machado FA, Costa WS. A rare variation in the high division of the sciatic nerve surrounding the

High division of sciatic nerve results in piriformis syndrome, sciatica, Failed sciatic nerve block in anesthesia, nerve injury during deep intramuscular injections.

Compression of sciatic nerve any where during its course may contribute to clinical conditions like sciatica and piriformis syndrome. Entrapment of the nerve within the piriformis muscle is one of the reasons of its compression, the condition being called 'piriformis syndrome. Diagnosis of unilateral division of piriformis is very important, as this will solve dilemma of surgeons as to why the symptoms, signs and also the effects of treatment of piriformis syndrome differ on two sides in same person^[6].

During the sciatic nerve block, the local anesthetic medication is infiltrated into the connective sheath around the nerve. Complete sciatic nerve blockage does not occur if the sciatic nerve is present as separately sheathed bundles upto the lower gluteal level. This condition, if present, may lead to the failure of sciatic nerve block even after multiple punctures and attempts^[7].

CONCLUSION: The knowledge regarding the level of division of the sciatic nerve and the location where it leaves the pelvis is of great importance. While seeing a single cadaver, we can't come to a conclusion but with the help of various previous studies, we have found that this variation is very rare. Thus awareness regarding this variation among surgeons and anesthetics is necessary to avoid surgical errors.

superior gemellus muscle. European journal of Morphology. 2003; Vol-41(1); p.41-2.

3. Vojnosanit Pregl. The level of sciatic nerve division and its relation to the piriformis muscle. PubMed 2005 Jan; Vol-62(1); p.45-9.

4. Prathiba K, Seema Madan, Udaya Kumar P, Dharmendar P, Nisha. A cadaveric study on anatomical variation of sciatic nerve in relation to piriformis muscle in Andhra Pradesh region. IJCRR 2013 Nov; Vol-5(21); p.56-60

5. Anne M. R. Agur, Arthur F. Dally; Relationship of sciatic nerve to piriformis. Grant's atlas of anatomy, 13th edition, Lippincott Williams & Wilkins; 2013; p.398.

6. Keith L. Moore, Arthur F. Dally, Anne M. R. Agur; Edited Clinically Oriented Anatomy. 6th edition, Lippincott Williams & Wilkins; 2010; p.582

7. Ronald D. Miller, Edited Miller's Anesthesia Volume 2; 7th edition; Churchill Livingstone Elsevier; 2010; p.1659

Cite this article as: Tanvi Mahajan, Bhosgikar Anup, N.G.Mulimani. Variation in the division of sciatic nerve: A case report. Journal of Ayurveda and Holistic Medicine (JAHM). 2014; 2(4).p.60-63

Source of support: Nil, Conflict of interest: None Declared.