

Case Report



Ayurvedic Management of Choroidal Osteoma: A Case Report

¹Sreekanth N Parameswaran, ²N Narayanan Namboothiri, ³Sreekala N P, ⁴*Basima A, ⁵Sumesh Soman, ⁶Krishnendu Sukumaran

ABSTRACT:

Background: Choroidal osteoma, a rare benign intraocular tumor characterized by mature bone replacing the choroid, often leads to vision loss due to complications like choroidal neovascularization (CNV) and subretinal fluid. Conventional anti-VEGF injections often face symptom recurrence. **Case:** A 47-year-old female presented on June 16, 2023, with progressive vision loss in her right eye since 2013, confirmed as peripapillary choroidal osteoma with subretinal fluid and CNV via fundoscopy and OCT. **Intervention:** After recurrent symptoms/side effects from anti-VEGF injections, Ayurvedic management began in June 2023, classifying the condition as 'Dwiteeya Patalagata Kaphaja Timira'. Treatments included oral medicines (e.g., *Kanjanara guggulu*, *Varanadi kashayam*) and external therapies (e.g., *Seka [eyewash]*, *Vidalaka [medicated-paste to eyelids]*, *Tarpanam [medicated-ghee retention over eyes]*) targeting *Kapha* imbalance and vitiated *Dhatu*s. **Outcome:** Ayurvedic management improved visual acuity, reduced sub-retinal fluid (SRF) and prevented CNV recurrence. Vision remained stable at the January 2025 follow-up. **Conclusion:** This case suggests Ayurvedic management is a potential complementary approach for choroidal osteoma, though larger studies are needed confirm effectiveness due single-case limitations.

KEYWORDS: Case report, choroidal osteoma, choroidal fluid loculation, *Kanjanara guggulu*, *Timira*.

RECEIVED ON:

05-07-2025

REVISED ON:

18-07-2025; 23-09-2025

ACCEPTED ON:

08-11-2025

Access This Article Online:

Quick Response Code:



Website Link:

<https://jahm.co.in>

DOI Link:

<https://doi.org/10.70066/jahm.v13i10.2189>

Corresponding Author Email:

drbasimaa8@gmail.com

CITE THIS ARTICLE AS

Sreekanth N Parameswaran, N Narayanan Namboothiri, Sreekala N P, Basima A, Sumesh Soman, Krishnendu Sukumaran. Ayurvedic Management of Choroidal Osteoma: A Case Report. *Journal of Ayurveda and Holistic Medicine (JAHM)*.2025;13(10):88-97



1. INTRODUCTION

Choroidal osteoma (ICD-10:D31.3) is a rare, benign, intraocular-tumor, commonly situated near the optic disc, with approximately 86% of reported cases in women. It appears as a yellow-orange plaque with well-defined scalloped margins, causing blurred vision, metamorphopsia, and scotoma. Etiology is unclear, with unproven theories of osseous choristoma due to its peripapillary location, secondary ossification from inflammation/trauma, or endocrine influence (e.g., pregnancy). [1, 2, 3]

This case is unique due to its extremely low incidence rate, and the absence of specific treatments, with management primarily focusing on complications such as progressive retinal atrophy and CNV. [2, 4] Approaches such as surgical removal, laser treatments, and anti-vascular endothelial growth factor (anti-VEGF) medications have been used to address secondary CNV, with the latter proving most effective. [5] This report explores Ayurvedic management as a potential complementary strategy, though its efficacy warrants validation through larger, controlled studies.

2. CASE REPORT

Clinical presentation: A 47-year-old female from Bangalore presented on June 16, 2023, with progressive diminished central vision, difficulty with near and distance vision, in her right eye (RE) since June 2013. She has no pain, redness, or floaters.

History: She was non-diabetic and non-hypertensive, and diagnosed with choroidal osteoma in June 2013. She received anti-VEGF injections (Avastin) in 2013, 2018, and three times in 2023 (last on May 5, 2023). But

discontinued all conventional medication following dizziness and vomiting after the last injection. Ayurvedic management was initiated on June 16, 2023. Her lifestyle was sedentary, with a *Kapha-kara* (that which increases *Kapha dosha*) and *Viruddha-ahara* (incompatible food) diet. Family history was negative for ocular or systemic diseases.

Clinical findings: Visual Acuity (VA): Unaided distant visual acuity (DVA) was LogMAR 0.84 (6/36- 1) in the RE and LogMAR 0.0 (6/6) in the left eye (LE), with no improvement with glasses in the RE. Near vision was N24 (RE) and N6 (LE) with +1.75 D spherical correction. Intraocular Pressure (IOP): 17 mmHg (RE) and 16 mmHg (LE). Anterior Segment was normal, but lenticular changes were noted bilaterally. Radial OCT (Optical Coherence tomography) revealed CNV, along with sub-retinal fluid (SRF), hyper-reflective lesion, intra-retinal hypo-reflective spaces, and choroidal thickening (**Fig. 1 and 2**). Fundoscopy showed a characteristic peripapillary lesion with scalloped margins in the RE (**Fig. 3**). The LE was normal.

Ayurvedic examination (*Dashavidha pareeksha*):
Prakruthi: Kapha-Vata, *Vikruthi Hetu:* Ahara- Kapha-kara, Vihara –Virudhahara sevana, Manasika –Achinta; *Dosha* –Kapha; *Dushya:* Rasa, Raktha, Mamsa, Meda; *Desha:* Anupa; *Sara:* Rasa, Raktha, Mamsa, Meda; *Samhana:* Madhyama; *Satva:* Madhyama; *Satmya:* Sarvarasa satmaya; *Bala:* Madhyama; *Pramana:* Madhyama; *Ahara Shakti:* Madhyama; *Vaya:* Madhyama.

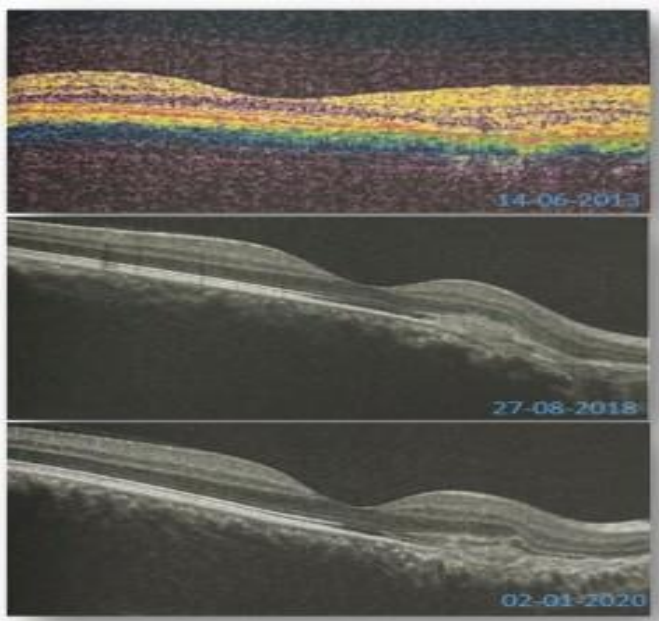


Figure – 1: June 14, 2013, OCT scan shows CNV and subretinal fluid in the macula. Subsequent scan (August 27, 2018 and January 2, 2020) consistently reveal a hyper-reflective sub-RPE lesion with a spongy appearance.

epithelium (RPE) with a characteristic ‘spongy’ or heterogeneous texture due to its calcified nature, accompanied by choroidal thickening (*). The retina in the central region shows noticeable elevation (a, b, c) with disruption of the retinal layers above the lesion, including intra-retinal hypo-reflective spaces (*) and hyper-reflective lamellar lines (*). SRF is present (*), along with choroidal loculation of fluid (*). Additionally, outer retinal tubulation (ORT) features are observed, characterized by vertical tubular lamellae (*) and horizontal tubular lamellae (*), which are indicative of retinal degeneration in choroidal osteoma. The corresponding fundus examination shows an orange-yellow choroidal osteoma at the macula with associated sub-retinal hemorrhage. OCT dated 12-04-22, 04-06-22, and 08-06-23 shows central subfield thickness (CSF) of 287 µm, 328 µm and 294 µm, respectively, possibly due to increased SRF caused by the osteoma’s mass effect.

Provisional diagnosis, differential diagnosis, and diagnosis: A provisional diagnosis of a choroidal lesion was made based on funduscopy showing a peripapillary lesion with scalloped margins. While Choroidal hemangioma was initially considered due to location, it was excluded based on its characteristic red-orange, ill-defined appearance and vascular origin. In contrast, the observed lesion—orange-yellow with well-defined geographic borders—was consistent with choroidal osteoma. OCT-Macula revealed intra-retinal hypo-reflective space, SRF, and choroidal hyper-reflectivity, confirming the diagnosis of choroidal osteoma. [2, 3]

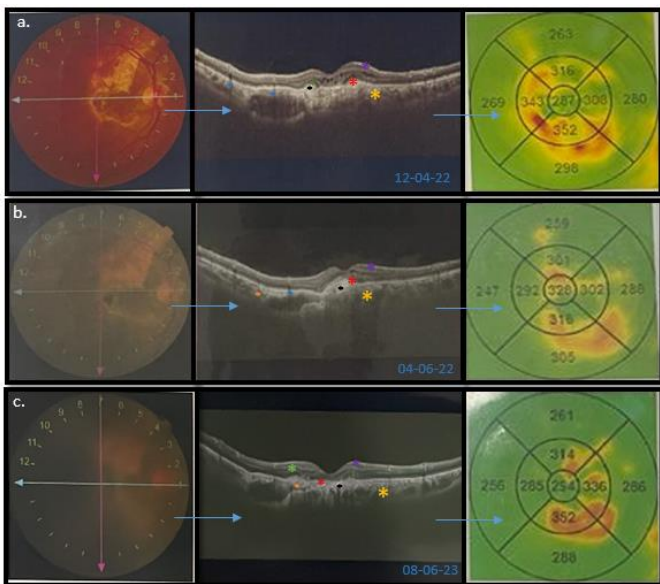


Figure – 2: Radial OCT of a choroidal osteoma reveals a hyper-reflective lesion beneath the retinal pigment

Timeline- Table – 1

Year	Incidence/intervention
Jun. 2013	Diminished vision (RE); Presence of CNV and subretinal fluid in the macula Diagnosed as starting stage of choroidal osteoma VA: 6/36-1; Received anti-VEGF injection; Vision stable then
Aug. 2018	Vision deteriorated [6/60 (RE)] OCT- Macula confirmed choroidal osteoma with a Hyper-reflective sub-RPE lesion with a spongy appearance Received anti-VEGF injection; Vision stable
Jan. 2020	Symptoms recurred [VA: 6/60 (RE)] Hyper-reflective sub-RPE lesion with a spongy appearance remained consistent in the OCT scan Received anti-VEGF injection; Vision improved to 6/36
Apr- Jun 2022	Vision worsened; OCT showed elevated SRF; VA: 6/60 (RE);
July- Dec 2022	The patient discontinued eye check-ups & treatment for 6 months.
Feb- May 2023	Received 3 anti-VEGF injections (last on 05/05/23); experienced dizziness, vomiting. [VA improved to 6/36 from 6/60 (RE)]
Jun-Jul 2023	OCT showed SRF, choroidal hyper-reflectivity (08/06/23); Started Ayurvedic medications at OPD on 16/06/23; VA: 6/36-1; The patient experienced mild clarity of vision in July.
Dec. 2023	OCT showed reduced SRF; VA: 6/36 (RE)
Feb-Mar 2024	Ayurvedic IP management started on 18/02/24; VA improved to 6/36+1 on 24/02/24; Patient was discharged on 02/03/24; Advised to continue discharge medicines.
April 2024	First follow-up on 19/04/24; VA improved to 6/24 (RE); OCT showed marked reduction in SRF and intra-retinal hypo reflective space.
June 2024	Second follow-up on 10/06/24; vision stable
Sep. 2024	Third follow-up on 29/09/24; OCT- Macula showed no recurrence of CNV- associated signs; vision improved to 6/18 - 1;
Jan. 2025	Fourth follow-up on 26/01/25; vision stable

Out-patient (OP) phase: The aim was *Shamana (palliation)* of Kapha and involved *dhatu (tissue)* vitiation. The patient took *Guggulu Tiktaka Grutham* at bedtime with lukewarm water as *anupana*. This method ensured high home compliance and low burden, especially after adverse effects of intravitreal therapy. Clinical monitoring and OCT findings during OP follow-

up determined readiness for inpatient treatment. (Table 1; doses/anupana in Tables 2–3).

In-patient (IP) phase: The regimen was intensified with two additional internal medicines, *Varanadi Kashayam* and *Kanjanara Guggulu* to enhance *Kapha–Medas* pacification and address suspected *granthi/arbuda*–like pathology. External ocular and systemic external

procedures were added in a structured schedule: *Seka* (7 days), *Vidalaka* (6 days), *Anjana* (6 days), *Shirodhara* (7 days), *Siroveshtanam* (5 days), and *Tarpanam* (7days).

Rationale for change OP to IP was criteria based escalation aligned with the patient's disease status and safety considerations: (i) Persistent SRF/CNV on OCT

despite prior anti-VEGF; (ii) need for multi-modal therapy to resolve *srotorodha* (*channel obstruction*) (iii) supervised delivery to ensure dose fidelity, monitoring, and timely adjustments.

Therapeutic intervention: The treatment protocols are listed in Tables 2 and 3

Table 2: Oral medicines

Medicine	Rationale	Dosage	Anupana	Time	Duration
<i>Varanadi kashayam</i> [6]	Pacifies <i>Kapha</i> and <i>Medas</i>	60ml	Lukewarm water	Twice daily in empty stomach	13 days 18/02/24-02/03/24
<i>Kanjanara guggulu</i> [7]	Indicated in tumor management	1 tab	With kashayam	Twice daily in empty stomach	13 days 18/02/24-02/03/24
<i>Guggulu tiktaka grutham</i> [8]	Indicated in tumor management	1 tsp	Lukewarm water	Bed time	260 days 16/06/23-02/03/24

Table 3: External therapies. [9]

Therapy	Medicine	Procedure	Time	Duration
<i>Seka</i>	<i>Triphala Yashtimadhu Kwatha</i>	30ml decoction poured over closed eyes.	Evening	7 days 18/02/24- 24/03/24
<i>Vidalaka</i>	<i>Mukkadi gutika, Karuthavettu</i>	Paste applied over eyelid.	Morning & evening	6 days 19/02/24– 24/03/24
<i>Anjana</i>	<i>Chandanadi Anjana</i>	Application of medicine to the palpebral conjunctiva.	Morning	6 days 19/02/24– 24/03/24
<i>Shirodhara</i>	<i>Varanadi kashayam, Amrtotharam kashayam</i> (2 L)	<i>Kashayam</i> poured slowly on the forehead.	Morning	7 days 24/02/24– 01/03/24
<i>Siroveshtanam</i> [10]	45g <i>Chooranam</i> of <i>Musta, Amalaki, kachooradi, karuthavattu gutika</i> in 600ml of <i>Triphala kashayam</i>	Paste smeared over gauze, tied around head.	Evening	5 days 19/02/24– 23/03/24
<i>Tarpanam</i>	<i>Anjana grtham + Triphala grtham</i> (40ml)	A barrier of black gram flour is constructed around both eyes. Medicated ghee is then poured into each eye sequentially, and the patient is instructed to blink slowly.	Evening	7 days 24/02/24– 01/03/24

Outcome and follow-up: During IP management (24/02/24), the unaided DVA improved to LogMAR 0.78 (6/36+1) in the RE. On follow-up (19/04/24), VA further improved to LogMAR 0.60 (6/24), with near vision N18. Fundus showed hemorrhage resolution, and OCT-Macula depicted a marked reduction in SRF (**Fig. 3**). The OCT-Macula (29/09/24) report showed no recurrence of

CNV or associated signs, and VA further improved to 6/18-1 (RE). Regular follow-ups were planned. The quantitative reduction in CSF (280 µm to 232 µm) over 10 months of Ayurvedic treatment suggests effective SRF management (**Table 4**), though the single-case limits generalizability, necessitating further studies

Table 4

Date	Central subfield thickness (CSF)	Treatment phase
12/04/22	287 µm	2 years of conventional treatment
04/06/22	328 µm	2 years of conventional treatment
08/06/23	294 µm	3 years of conventional treatment
16/06/23	Discontinued conventional medications, including anti-VEGF therapy, due to side effects (dizziness and vomiting), and Ayurvedic management was initiated.	
20/12/23	280 µm	6 months Ayurvedic treatment
25/01/24	270 µm	7 months Ayurvedic treatment
15/04/24	232 µm	10 months Ayurvedic treatment

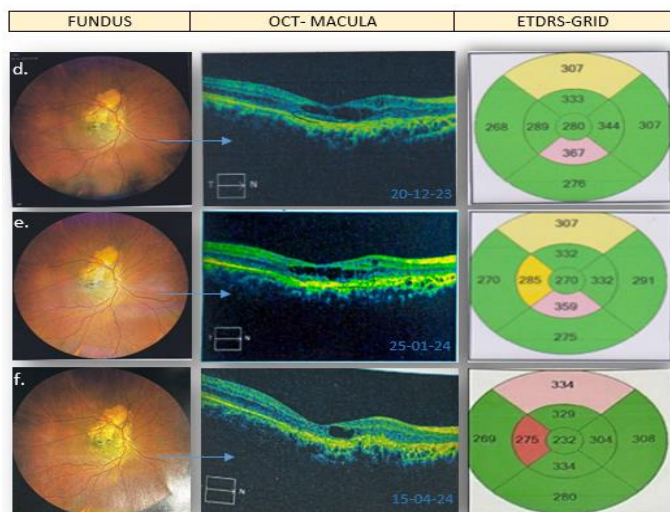


Figure-3: Fundus reveals a peripapillary lesion with scalloped margins extending to the fovea in the RE. OCT-Macula shows a stable hyper-reflective sub-RPE lesion with a 'spongy' texture, consistent with choroidal osteoma. Notably, there was a slight reduction in SRF (CSF: 270 µm) (**Fig.3.e**) compared to the scan on 20/12/23 (CSF: 280 µm) (**Fig.3.d**). A marked reduction in SRF (CSF: 232 µm) and intra-retinal hypo-reflective space, indicates cessation of hemorrhage (15/04/24) (**Fig.3.f**).

Table 5

Date	Visit	Distant VA (Snellen)	Distant VA (logMAR)	Notes
Dec 2023	Pre-Ayurveda baseline	6/60	1	SRF present; CNV signs on OCT
24-Feb-24	IP admission	6/36+1	0.76	On Ayurveda; OCT still showed SRF

14-Apr-24	OP follow-up	6/24	0.6	Marked SRF reduction
10-Jun-24	OP follow-up	6/24	0.6	Vision stable
29-Sep-24	OP follow-up	6/18-1	0.50	No CNV-associated signs
26-Jan-25	OP follow-up	6/18-1	0.50	Stable

Adherence and tolerability.

During the OP phase, the patient reported good adherence to the prescribed oral regimen, with no documented missed-dose. During the IP phase (18 Feb–2 Mar 2024), all internal medicines and external/ocular procedures were administered under supervision, and no doses were missed. Across both phases, no Ayurveda-related adverse events were recorded; specifically, no reports of gastrointestinal intolerance, dermatologic reactions, headaches, ocular surface irritation beyond transient procedure-related sensations, or systemic complaints requiring dose modification. The prior adverse effects (dizziness/vomiting) occurred after the last intravitreal anti-VEGF injection (May 2023), were not observed after initiating Ayurvedic Treatment.

3. DISCUSSION

Complications like CNV, SRF loculation, and ORT in Choroidal osteoma impact visual prognosis. [11, 12] The patient’s late-stage presentation and uncorrected vision limited full recovery. Although, anti-VEGF injections offered initial symptom relief, symptom recurrence necessitated alternative management.

Ayurveda correlates choroidal osteoma with ‘*Dwiteeyapatalagata Kaphaja Timira*’ (NAM code_HG-1.2, HG-1.13), given diminished central vision, distant and near vision (features of *Timira* involving the 2nd

patala, specifically the choroid [13] The patient’s dietary habits (excessive intake of sweet and oily food) and sedentary lifestyle caused vitiation of *Kapha Dosha*, *Mamsa* (muscle), *Rakta* (blood), and *Meda* (fat) *dhatu*s, which contributed to tumor formation, SRF and hemorrhage. [14]

The Ayurvedic management [Tables 2 and 3] targeted *Kapha* imbalance, vitiated *Dhatu*s, and associated complications (**Diagram 1**). *Kanjanara guggulu*, was used to balance *Kapha Dosha* and promotes elimination of inflammatory toxin by breaking down hardened *Kapha*, and preventing further accumulation. [15] Therapies like *Seka*, *Vidalaka*, *Shirodhara*, *Siroveshtanam*, and *Tarpanam* aided in symptom relief and enhanced VA.

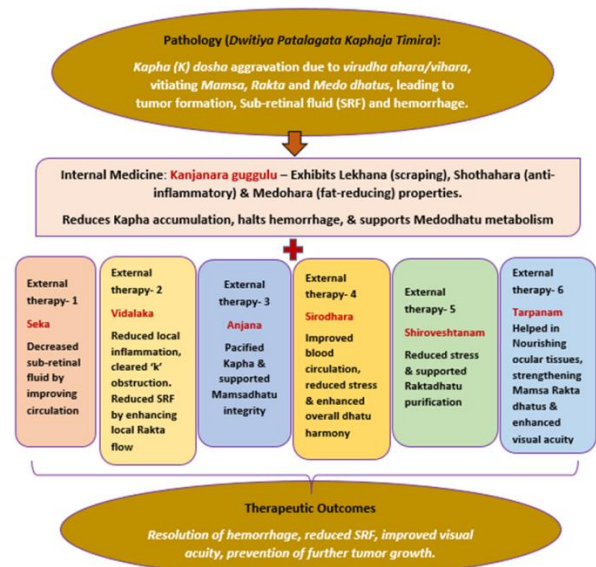


Diagram 1- Mode of action of treatment

Diagram 1 - Flowchart depicts Ayurvedic mode of Action of internal and external treatments in managing choroidal osteoma (*Dwitiyuapatalagata Kaphaja Timira*), illustrating how they address *Kapha dosha* imbalance, vitiated *dhatu*s, and associated complications.

The case's strengths lie in Ayurveda's efficacy in managing this rare ocular condition, achieving resolution of CNV-associated signs despite a late presentation. Limitations include late-stage presentation, which restricted full visual recovery. Regular follow-ups are planned to monitor recurrence.

This case underscores the value of integrating Ayurveda with modern diagnostics for rare ocular conditions, suggesting a need for further research into Ayurveda's role in ophthalmology.

4. CONCLUSION

Choroidal osteoma is a rare condition with an uncertain etiology. Treatments included oral medicines (e.g., *Kanjanara guggulu*, *Varanadi kashayam*) and external therapies (e.g., *Seka [eyewash]*, *Vidalaka [medicated-paste to eyelids]*, *Tarpanam [medicated-ghee retention over eyes]*) targeting *Kapha* imbalance and vitiated *Dhatu*s. The patient is given the said treatments for period of 13 months with regular follow-up. Ayurvedic management aimed at *Kapha* balance and the *Dwiteeyapatalagata Kaphaja Timira* framework was associated with observed improvements in advanced stage, however causality cannot be inferred from a single case.

Declaration of Patient Consent – The authors confirm that they have acquired a patient consent form, in which the patient or caregiver has granted permission for the publication of the case, including

accompanying images and other clinical details, in the journal. The patient or caregiver acknowledges that their name and initials will not be disclosed, and sincere attempts will be undertaken to safeguard their identity. However, complete anonymity cannot be assured.

Patient perspective - Since 2013, I struggled with blurry vision in my RE from choroidal osteoma. Injections helped me briefly, but symptoms recurred, and the last injection in 2023 caused dizziness and vomiting. I started Ayurveda treatment in June 2023. The doctors explained my condition well, linking it to my diet and lifestyle. The treatments, like eye-washes and herbal medicines, were gentle. Gradually my eyesight improved significantly, and I feel healthier. I am thankful and hopeful continuing my follow-ups.

Authors Details:

¹Chief Medical Officer, Sreedhareeyam Ayurvedic Eye Hospital and Research Centre, Sreedhareeyam Ayurvedic Research and Development Institute, Nelliakkattumana, Kizhakombu PO, Koothattukulam-686662. Ernakulam, Kerala, India.

²Chief Physican, Sreedhareeyam Ayurvedic Eye Hospital and Research Centre, Sreedhareeyam Ayurvedic Research and Development Institute, Nelliakkattumana, Kizhakombu PO, Koothattukulam-686662. Ernakulam, Kerala, India.

³Deputy Chief Physician, Sreedhareeyam Ayurvedic Eye Hospital and Research Centre, Sreedhareeyam Ayurvedic Research and Development Institute, Nelliakkattumana, Kizhakombu PO, Koothattukulam-686662. Ernakulam, Kerala, India.

⁴Research Coordinator, Sreedhareeyam Ayurvedic Research and Development Institute, Nelliakkattumana, Kizhakombu PO, Koothattukulam-686662. Ernakulam, Kerala, India

⁵Research Officer, Sreedhareeyam Ayurvedic Research and Development Institute, Nelliakkattumana, Kizhakombu PO, Koothattukulam-686662. Ernakulam, Kerala, India.

⁶Research Coordinator, Sreedhareeyam Ayurvedic Research and Development Institute, Nelliakkattumana, Kizhakombu PO, Koothattukulam-686662. Ernakulam, Kerala, India.

Authors Contribution:

Conceptualization and clinical management: NPS, NN

Data collection and literature search: AB, KS

Writing –original draft: AB, SS

Reviewing & editing: SNP, KS, NN, NPS

Approval of final manuscript: All authors

Acknowledgements:

The authors acknowledge Sreedhareeyam Ayurvedic Eye Hospital and Research Centre, and Sreedhareeyam Farm Herbs India Pvt. Ltd, for their contribution in preparing this case report. Greatly grateful to Sreedhareeyam and the authors/editors/publishers of all those articles, journals, and books from where the literature of this article has been reviewed and discussed.

Declaration of Generative AI

The authors declare this manuscript was written without the use of generative artificial intelligence tools. All the content, including text generation, data analysis and references was developed and reviewed by the author without assistance from AI technologies.

Conflict of Interest – The authors declare no conflicts of interest.

Source of Support – The authors declare no source of support.

Additional Information:

Authors can order reprints (print copies) of their articles by visiting:

<https://www.akinik.com/products/2281/journal-of-ayurveda-and-holistic-medicine-jahm>

Publisher's Note:

Atreya Ayurveda Publications remains neutral with regard to jurisdictional claims in published maps, institutional affiliations, and territorial designations. The publisher does not take any position concerning legal status of countries, territories, or borders shown on maps or mentioned in institutional affiliations.

REFERENCES:

1. Friedman SL, Pinzani M. Hepatic fibrosis 2022: Unmet needs and a blueprint for the future. *Hepatology*. 2022; Feb;75(2):473-488. <https://doi.org/10.1002/hep.32285>
2. Popper H, Uenfriend S. Hepatic fibrosis. Correlation of biochemical and morphologic investigations. *Am J Med*. 1970; Nov;49:707-21. [https://doi.org/10.1016/s0002-9343\(70\)80135-8](https://doi.org/10.1016/s0002-9343(70)80135-8)
3. Albanis E, Friedman SL. Hepatic fibrosis. Pathogenesis and principles of therapy. *Clin Liver Dis*. 2001; May;5(2):315-34, v-vi. [https://doi.org/10.1016/s1089-3261\(05\)70168-9](https://doi.org/10.1016/s1089-3261(05)70168-9)
4. Sun YM, Chen SY, You H. Regression of liver fibrosis: evidence and challenges. *Chin Med J (Engl)*.2020;Jul 20;133(14):1696-1702. <https://doi.org/10.1097/CM9.0000000000000835>
5. Berumen J, Baglieri J, Kisseleva T, Mekeel K. Liver fibrosis: Pathophysiology and clinical implications. *WIREs Mechanisms of Disease*. 2021;13(1):e1499. <https://doi.org/10.1002/wsbm.1499>
6. Patil V, Rodd M. AYURVEDIC MANAGEMENT OF LIVER CIRRHOSIS WITH PORTAL HYPERTENSION. *Journal of Ayurveda and Holistic Medicine (JAHM)*. 2021; Jul;9(3). <https://jahm.co.in/index.php/jahm/article/view/444>
7. Singh A, Singh G, Patwardhan K, Gehlot S. Development, Validation, and Verification of a Self-Assessment Tool to Estimate Agnibala (Digestive Strength). *J Evid Based Complementary Altern Med*. 2017; Jan;22(1):134-140. <https://doi.org/10.1177/2156587216656117>
8. Gora RH, Baxla SL, Kerketta P, Patnaik S, Roy BK. Hepatoprotective activity of Tephrosia purpurea against arsenic induced toxicity in rats. *Indian J Pharmacol*. 2014; Mar-Apr;46(2):197-200. <https://doi.org/10.4103/0253-7613.129317>
9. Kumar S, Singh A, Kumar B. Identification and characterization of phenolics and terpenoids from ethanolic extracts of *Phyllanthus* species by HPLC-ESI-QTOF-MS/MS. *J Pharm Anal*. 2017; Aug;7(4):214-222. <https://doi.org/10.1016/j.jpha.2017.01.005>
10. Kassuya CA, Leite DF, de Melo LV, Rehder VL, Calixto JB. Anti-inflammatory properties of extracts, fractions and lignans isolated from *Phyllanthus amarus*. *Planta Med*. 2005; Aug;71(8):721-6. <https://doi.org/10.1055/s-2005-871258>
11. Hassan Bulbul MR, Uddin Chowdhury MN, Naima TA, Sami SA, Imtiaj MS, Huda N, Uddin MG. A comprehensive review on the diverse pharmacological perspectives of *Terminalia chebula* Retz. *Heliyon*. 2022; Aug 14;8(8):e10220. <https://doi.org/10.1016/j.heliyon.2022.e10220>
12. Choi MK, Kim HG, Han JM, Lee JS, Lee JS, Chung SH, Son CG. Hepatoprotective Effect of *Terminalia chebula* against t-BHP-Induced Acute Liver Injury in C57/BL6 Mice. *Evid Based Complement Alternat Med*. 2015; 2015:517350. <https://doi.org/10.1155/2015/517350>

13. Kantharia C, Kumar M, Jain MK, Sharma L, Jain L, Desai A. Hepatoprotective Effects of Liv.52 in Chronic Liver Disease Preclinical, Clinical, and Safety Evidence: A Review. *Gastroenterology Insights*. 2023; 14(3):293-308. <https://doi.org/10.3390/gastroent14030021>
14. Parasuraman S, Kumar E, Kumar A, Emerson S. Free radical scavenging property and diuretic effect of triglize, a polyherbal formulation in experimental models. *J Pharmacol Pharmacother*. 2010; Jan;1(1):38-41. <https://doi.org/10.4103/0976-500X.64535>
15. Soleimani D, Ranjbar G, Rezvani R, Goshayeshi L, Razmpour F, Nematy M. Dietary patterns in relation to hepatic fibrosis among patients with nonalcoholic fatty liver disease. *Diabetes Metab Syndr Obes*. 2019; March 12;12:315-324. <https://doi.org/10.2147/DMSO.S198744>