



CASE REPORT

AYURVEDIC APPROACH TO OVARIAN CYST – A CASE STUDY

MANDWARIYA SHILPA¹ MISHRA OMNATH² MANDWARIYA SOURABH³

ABSTRACT:

Ovarian cysts are fluid-filled sacs or pockets in an ovary or on its surface. Women have two ovaries, each about the size and shape of an almond on each side of the uterus. Ovum which develop and mature in the ovaries, are released in monthly cycles during the childbearing years. In the present case study, a patient of age 18 years of a large right ovarian cystic mass who was advised for removing the cyst by allopathic hospital came to take Ayurvedic consultation. The patient was treated with the concept of kapha dusti janya vyadhi. Ayurvedic treatment of kapha dushti include shodhana, shaman and chedana karma. Therefore assuming as kaphaj granthi line of treatment was planned which can correct the kapha dosha. Even though significant research is taking place in this area but no effective treatment other than surgical management is available till date. No case study describing such a huge ovarian cyst treated by Ayurvedic medicines is published yet. The management of ovarian cyst with Ayurvedic formulations has no adverse effect. After a treatment of three months, the patient came with drastic changes in signs and symptoms, with simultaneous decrease in size of ovarian cyst represented by pelvic ultrasonography (USG). The patient is also advised to follow pathya apathya as mentioned.

Key words: Ovarian cyst, Kaphaj granthi, Ayurveda

¹ Ayurveda Medical Officer, Government Ayush Dispensary, Sejpuriya, District – Mandsaur (MP), INDIA

² District AYUSH Officer, Mandsaur (MP), INDIA

³ Medical Officer, Indira Gandhi District Hospital, Mandsaur (MP), INDIA

INTRODUCTION

The ovaries are part of the female reproductive system. They are located in the lower abdomen on both sides of the uterus [1]. Women have two ovaries that produce eggs as well as the hormones estrogen and progesterone. Most ovarian cysts develop as a result of the normal function of menstrual cycle. These are known as functional cysts.

Around the midpoint of menstrual cycle, an egg bursts out of its follicle and travels down the fallopian tube in search of sperm to cause fertilization. A follicular cyst begins when something goes wrong and the follicle does not rupture or releases its egg. Instead it grows and turns into a cyst. A large ovarian cyst can cause abdominal discomfort. Allopathic treatment includes the prescription of birth control pills to reduce the chances of developing new cysts in future but it causes the hormonal imbalance. Surgery may be prescribed for the removal of a large cyst which doesn't look like a functional cyst and is growing and persists through two or three menstrual cycles. Ovarian cysts can be completely cured by herbal remedies without having any adverse effect on hormonal balance [2].

Localized nodular swelling/growth has been referred under the name of *Granthi* that develops due to localization of morbid body humors in body tissue [3]. Pathogenesis

of *Granthi* is propounded as when morbid *Tridoshas*, vitiate *Rakta* (blood), *Mamsa* (fleshy/muscles) and *Meda* (fat/adipose tissue) that are admixed with *Kapha* produce rounded, protuberant, knotty or glandular and hard swelling called *Granthi* [4]. Etiopathogenesis, clinical features and treatment of *Granthi* are identical for any body part, however few clinical features present due to a specific location of the disease as a result of anatomical and physiological disturbance [5].

CASE HISTORY

A female patient of age 18 years came to outpatient department of Govt. Ayurveda Dispensary for treatment. On history taking the following symptoms were present in patient:

- White discharge per vaginal since six months
- Abdominal fullness since three months
- Persistent dull aching generalized abdominal pain since two months.
- Occasional sudden severe lower abdominal pain
- Pain accompanied by fever, nausea and vomiting.

On examination following signs were elicited:

- Patient was afebrile and anemic
- Per abdominal examination shows tenderness at suprapubic region. No guarding or rigidity present.

- Per abdominal examination shows a soft to hard mass of approximate 10.0 x 8.0 cm in Suprapubic and Right iliac region
- No other positive findings noted

Patent was advised for an abdominal and pelvic ultrasonography(USG). Patient has undergone an abdominal and pelvic USG on 24.03.2017 which revealed a large well

defined right ovarian cystic mass measures 12.8 x 11.9 x 7.3 cm with few septations and another cystic component inside the cystic mass. As the patient was only 18 years old so she was not willing for surgical process which was advised by a allopathic surgical specialist. So she decided to take Ayurvedic treatment for the lesion.

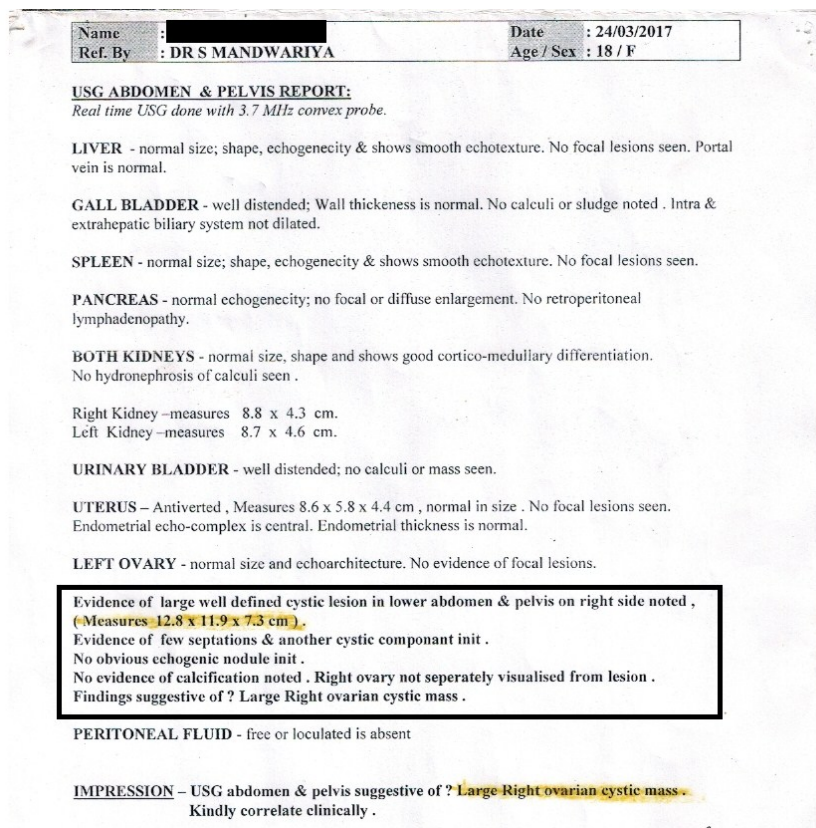


Fig. 1: USG Abdomen and Pelvis report (Before Treatment)

As according to Ayurvedic concept *vriddha dosha* should be palliated through appropriate drugs which balance that *dosha*. Therefore total *kapha shamak and chedana* chikitsa is given to the patient which was proved highly beneficial to the patient. The

line of treatment and prescription was as follows:-

1. *Kachnar guggul* 2 BD with lukewarm water
2. *Shankha vati* 2 BD
3. *Swarna bhasma* 1.2 mg
Herak(Vajra bhasma) 0.1 mg

Arka bhasma 10 mg

Rasasindoor 0.5 mg

Abhrak bhasma 0.4 mg

All the above medicines were mixed to prepare single dose. This dose was given two times a day with *madhu*.

4. *Pushyanug churna* 3 gm BD with rice water

5. *Kumaryasava* 10 ml BD with equal amount of water

Apathya

Patient was advised to avoid diet which increases *Vata* and *Pitta doshas* in the body like intake of dry foods, chips and sour foods like curd.

Pathya

Morning walk for minimum 30 minutes was advised along with meditation.

This above treatment was given to the patient for three month. Patient was advised for review monthly and whenever required. Patient symptoms got improved which was noticed on monthly visit. Patient was advised to continue same treatment except *shankha vati*. *Punarnava mandura* one tablet BD was added for six months. After nine months USG was repeated which show no evidence of focal lesion in right ovary.

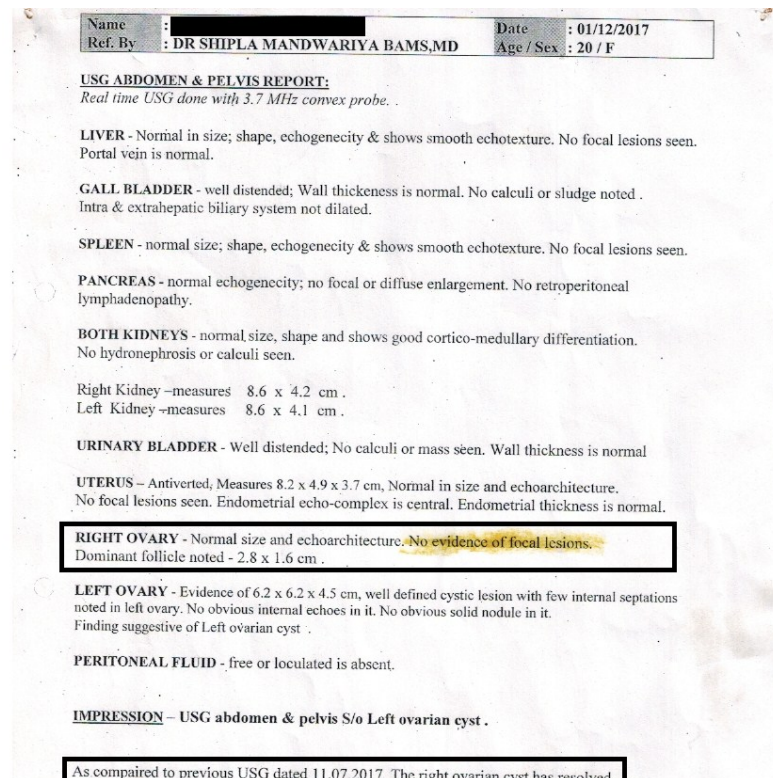


Fig. 2: USG Abdomen and Pelvis (After Treatment)

DISCUSSION

In the above prescription *kachnar guggul* is given. *Kanchnar Guggul* is a combination of ingredients such as *Kanchnar* (*Bauhinia Variegata*), *Triphala* [*Amalaki* (*Embllica officinalis*), *Haritaki* (*Terminalia chebula*) and *Bibhitaki* (*Terminalia bellirica*)], *Trikatu* [*Pippali* (*Piper longum*), *Marich* (*Piper nigrum*) and *Shunthi* (*Zingiber officinale*)], *Varun* (*Crataeva nurvala*), *Twak* (*Cinnamomum zeylanicum*), *Tejpatra* (*Eletteria cardamomum*) and *Shudh Guggul* (*Commiphora wightii*) herbal extract.

Kanchanara Guggulu is a classical Ayurvedic formulation, used for *Kapha* accumulations in the tissues. As *Kapha* moves deeper within the system, it may manifest as swollen lymph nodes, cysts or growths. Powerful decongestants such as *Kanchanara*, *Triphala* (a combination of fruits of *Terminalia chebula* Retz., *Terminalia belerica* Roxb., and *E. officinalis*) and *Trikatu* (*Zingiber officinale* Rosc., *Piper nigrum* L. and *Piper longum* L.) are mixed with *Guggulu* to break down and eliminate hardened *Kapha*. This detoxifying blend supports the proper function of the lymphatic drainage and digestive systems, aiding in the prevention of further *Kapha* accumulation. Its main ingredients *Kanchanara* (*Bauhinia variegata* L.), *Varuna* (*Crataeva nurvala* Buch.-Ham.), *Triphala*, *Trikatu*, *Trijataka* may also be useful in hypothyroidism. *Kanchanara Guggulu*

supports proper function of the lymphatic system, balances *Kapha Dosha*, promotes elimination of inflammatory toxins; it is alterative, anti-inflammatory and tonic which is administered in cysts, malignant ulcers, syphilis, fistula, scrofula, sinus, etc. *Kanchanara* is very useful in extra growth or tumors and helps in reducing bleeding^[6].

Shankha bhasma is also added in this treatment. *Shankha bhasma*, *Trikatu*, *Hingu*, *Vatsanabha*, *Kshara* and *Lavana* are commonly seen ingredients in all the types of *Shankha vati*. Classically, *Shankha Bhasma* is *Sheeta Veerya*, alkaline in nature, *Balya*, *Grahi*, *Varnya* and is indicated in *Amlapitta*, *Agnimandhya*, *Grahani*, *Parinama Shula*, and *Mukha Dhushika*^[7]. *Hingu* is a good digestive and appetizer. It pacifies *Vata* and *Kapha*; and diseases like *Shula*, *Gulma*, *Udara*, *Anaha* and *Krimi*^[8]. New pharmacological studies have almost confirmed the traditional uses of *asafoetida* as an antihelminthic, antispasmodic and antibacterial agent^[9]. *Shankha Vati* is known for its effective digestive action. The major area of action of *Shankha Vati* is gastro intestinal tract. *Shula* is most common indication of *Shankha Vati*^[10].

Suvarna bhasma and *Hirak bhasma* works as *rasayana* which shows antitumor, immunomodulator, non cytotoxic, antiangiogenic, and antioxidant properties^[11]. Therefore the drugs which help in immune-

modulation such as *swarna bhasma*, *heerak bhasm* etc. are added because they help in protecting the health and provide strength. *Abhrak Bhasma* increases physical stamina and endurance capacity. It strengthens the uterus and provides nutrition to ovaries. It increases skin glow and hemoglobin level [12]. *Pushyanug churna* is also given to the patient as she had complaint of white discharge. Most of the ingredients of *pushyanug churna* contain *Kashaya*, *Tikta rasa*, *Laghu*, *Ruksha guna*, *Sheeta veerya* properties. Due to *Kashaya*, *tikta rasa* it has *Grahi* action so it is indicated in all bleeding conditions. *Pushyanuga churna* is especially mentioned in *pradara rogas* in all classical books [13]. Excessive discharge is one of the *kapha vrudhi lakshana*. *Laghu*, *ruksha gunas* alleviates excessive *kapha* so it is beneficial in all *pradara rogas*. The patient is strictly advised to follow *pathya* and *apathya* because in absence this disease cannot be relieved.

CONCLUSION

In the present study it is observed that the patient got symptomatic relief in abdominal pain, abdominal bloating, weakness, fever, leucorrhoea as well as complete regression of right ovarian cyst without observing any adverse effect. It indicates that ayurvedic treatment can be an effective treatment for ovarian cyst where available options are limited. Hence further

clinical trials are needed which can definitely create new dimensions in the field of cyst treatment.

REFERENCES

1. J. Brontë Gaten. *Proceedings of the Royal Irish Academy. Section B: Biological, Geological, and Chemical Science*; Vol. 36 (1921 - 1924); pp. 65-90
2. Nelson-Al, G.J. (2010) Congenital anomalies and benign conditions of the ovaries and fallopian tubes. In: Hacker, N.F., Gambone, J.C. and Hobel, C.J., Eds., Hacker and Moore's Essentials of Obstetrics and Gynecology, 5th Edition, Saunders, Philadelphia, 248-255.
3. Vaidya Jadavji Trikamji Acharya. Sushruta, Sushruta Samhita, Nidana Sthana, Vatvyadhinidan Adhyaya, 1/3, 9th ed.; Varanasi:Chaukhamba Orientalia; 2007;256
4. Vaidya Jadavji Trikamji Acharya. Agnivesha, Charaka, Dridhabala, Charaka Samhita, Chikitsa Sthana, Shwayathu Chikitsa Adhyaya; 12/74; reprint ed. Varanasi: Chowkhambha Orientalia,; 2011; 488
5. Ibidem. Charak Samhita, Chikitsa Sthana, Shwayathu Chikitsa Adhyaya; 12/81; 489
6. Brahmashankar Mishra. Kachnar Guggul, Gutika Prakarna, [Ras Tantra Saar va Sidh Prayog Sangrah](#) (Vol. 1) Bhavamishra, Bhavaprakasha, Guduchyadi Varga, 103-104, 11th ed.; Varanasi:Chaukhamba Sanskrit Sanstana; 2004;336-7
7. Kashinatha Shastri. Rasa Tarangini of Sadananda Sharma, 11 ed.; Delhi:Motilal Banarasidas; 1989; 12/20-21, 20/83-86, 14/154-155 p.288 and 364
8. Chuneekar KC and Pandeya GS. Bhava Prakasha Nighantu of Bhavamishra; Haritakyadi Varga 100-101, Dhatvadi Varga 11-13, Dhatvadi Varga

- 203, Guduchyadi varga 219-20, Haritakyadi Varga 69-70; p.40, 613, 633, 414 and 21; Varanasi:Chowkhambha Bharati Academy; 2004
9. Milad Iranshahy, Mehrdad Iranshahi. Traditional uses, phytochemistry and pharmacology of asafetida (Ferula assa-foetida oleo-gum-resin)—A review, *Journal of Ethnopharmacology*, 2011;134:1-10.
 10. Chaturvedi K DV. A study on Shankhadi Vati on Udara Shoola, Post Graduate dissertation, Institute for Post Graduate Teaching and Research; 1996
 11. Chitta Ranjan Patra, Resham Bhattacharya, Priyabrata Mukherjee. Fabrication of Gold Nanoparticles for targeted therapy in pancreatic cancer. *Advanced Drug Delivery reviews*; 2010Mar8;62(3):346-361
 12. Sarkar PK, Prajapati PK, Choudhary AK, Shukla VJ, Ravishankar B. Haematinic evaluation of Louha bashma and Mandura bashma on HgCl₂-induced anaemia in rats, *Indian J Pharm Sci*; 2007;69:791-5
 13. M. Bhuvaneswari & Kishore Seetarama D. Role Of Pushyanuga Churna In Rakta Pradara, *IAMJ*; VOLUME 5, ISSUE 12, DECEMBER, 2017; 4467
- Cite this article as:** Mandwariya Shilpa, Mishra Omnath, Mandwariya Sourabh. Ayurvedic approach to ovarian cyst – a case study, *J of Ayurveda and Hol Med (JAHM)*.2018;6(4):94-100
- Source of support: Nil
- Conflict of interest: None Declared