



CLINICAL EVALUATION OF MODIFIED MANASHILADI LEPA IN THE PREVENTION OF POST- SURGICAL SCAR

SURESH Y¹ PRASHANTH BK² RAVI RAO³ PRASHANTH KEKUDA⁴

ABSTRACT

Background: Scar formation is an unavoidable consequence of post surgical wound healing and it is very disturbing for a person who is undergoing surgery and prevention is a cosmetic challenge. *Acharya Sharangadhara* in his book *Sharangadhara Samhita* has explained different types '*Bahya Kalpana*' among them *Lepa Kalpana* forms an important sub type which is widely used. *Manashiladi Lepa* is explained in '*Rasa Tantra Sara Va Siddha Prayoga Sangraha*' for the prevention of scar in the skin surface. The formulation contains ghritha and madhu which is to be mixed with the powder of the herbs told in the formulation. In the present scenario, the lepa kalpana is not liked by the patients as it leaves behind residuals on the skin surface and stains the cloth on contact. Hence a modified lepa in the form of ointment which contains reduced amount of oiliness and good packing is accepted by all. **Setting and design:** Randomized Control Clinical Trial was conducted on 100 Post- surgical patients who have undergone caesarian section. **Methods and materials:** 100 patients, divided in to 50patients each in group-A (Control) and group-B (Trial drug group). Group A patients were observed without application of ointmentand for Group B, *Manashiladi* ointment was applied thrice a day on the sutured area with a thickness of 2mm for 20 minutes. After 21 days the patients were assessed for scar marks over the sutured area. **Statistical analysis used:** The results are drawn after analyzing the findings by Wilcoxon Signed Rank Test and Mann-Whitney Rank Test. **Result:** In this study average days taken for wound healing in group B was 7 and in group A was 11. **Conclusion:** The trial drug Manashilaadi Ointment shown encouraging result in preventing scar formation , also it is recommended as a cost-effective, easy to prepare and partially effective therapy without producing any adverse effect.

Keywords: *Manashilaadi Lepa*, Ointment, Wound healing, Scar.

CTRI Registration - CTRI/2017/03/008147

¹Associate Professor, Dept. of Agadatantra, ³Professor, Department of Dravyaguna Alva's Ayurveda Medical College, Moodbidiri, Karnataka

²Principal, Prasanna Ayurveda Medical College , Belthangady (DK), Karnataka

⁴ Professor Dept. of Kriya Shareera Government Ayurveda Medical College , Shimog, Karnataka

Corresponding Email id:dr.sureshy@gmail.com Access this article online: www.jahm.in

Published by Atreya Ayurveda Publications under the license CC-by-NC-SA.

INTRODUCTION:

A good looking skin is a dream of any human being. Scar formation after surgical intervention Caesarian section is seen, leading to cosmetic derangement. Prevention of post-surgical scar is a cosmetic challenge. Prevention of scar will enhance the beauty of the skin of the patients who has undergone caesarian section during delivery. *Acharya Sharangadhara* in his book *Sharangadhara Samhita* has explained different types of formulations for usage out of which 'BahyaKalpana' is one[1]. *Lepa Kalpana* forms an important sub type of *Bahya Kalpana* which is widely used due to its action on the localized area of application. *Manashiladi Lepa* is explained in '*Rasa Tantra Sara Va Siddha Prayoga Sangraha*' for the prevention of scar in the skin surface[2]. But due to the presence of *Ghrita* in *Manashiladi Lepa*, it becomes difficult for the patients in carrying the formulation, difficult for large scale manufacturing and has a short shelf life. So it is modified in to ointment form and taken for clinical evaluation. Ointment formulation is a semisolid dosage form which is suitable for external application on skin. It is oily preparations that contain one or more active ingredients that is soluble or spread homogenously. Generally, ointment composed of active ingredient either powder or liquid that is incorporated into the oily semisolid

continuous phase. In Pharmaceuticals, ointment preparation is used to act as local treatment at application site, increasing the moisture of the skin (emollient effect).A good ointment must have an appealing texture, easy to use on skin characteristic as well as releasing its active ingredient from it. The patients will be able to carry the pack easily and the applicability of the ointment will be easy. Prevention of scar also depends on proper wound healing, There are many measures to create favorable conditions for wound healing, such as use of antiseptic solutions and antibiotics to combat the infection, inflammation and many agents to remove slough/dead tissues to shorten the inflammatory phase and thus promote the healing process [3].But these measures have failed to achieve good cosmetic effect by preventing the scar formation. This is why the search is still on to find out a drug or drug combination which can fulfill the optimal requirement. Ingredients of lepa like *Manashila* (Realgar), *Laksha* (Lacciferlacca) , *Haridra* (*Curcuma longa*) *Daruharidra* (*Berberis aristata* DC) and Honey are well known for its wound healing property. Active chemical constituents berberine in *Daruharidra* (*Berberis aristata* DC), Anthraquinones found in *Manjishtha* (*Rubiocordifolia* Linn.) are also proved to be effective. Large scale manufacturing of the modified ointment of

Manashilaadi Lepa will fulfill the long term need of a medication which can be applied easily by the patients to prevent the scars and enhance the cosmetic value. Which is also the prime need of today's cosmetic era, has been considered. Though the herbo mineral drugs are prescribed with high appreciation for healing purpose, they need scientific validation with proper study design. Keeping all these factors in view, the above compound formulation Modified *Manashiladi Lepa* (ointment) has been selected for clinical evaluation.

AIMS AND OBJECTIVES:

To modify *Manashiladi Lepa* into ointment form.

Analytical study of *Manashiladi* ointment.

To determine the clinical efficacy of *Manashiladi* ointment (trial drug) to prevent scar formation in post- operative case.

MATERIALS AND METHODS:

The work was carried out after obtaining approval from the Institutional Ethical committee, Alva's Ayurveda Medical College.

Collection of raw drugs and Ingredients -

The raw drugs were purchased from shop in Mangalore which deals with purchase and sale of genuine herbs. All the raw drugs were later certified as genuine samples by the Department of *Dravyaguna*, Alva's Ayurveda Medical College, Moodbidri, Karnataka.

The formulation contains following ingredients[4]: (used in equal proportions).

- Purified *Manashila* (*Shodhana* done by *Bhavana* in *Nimbu* rasa for 7 times- ref. *RasaTarangini*)
- *Ela* (*Elataria cardamom*)
- *Manjistha* (*Rubiaccordifolia*)
- *Laksha* (*Lacciferlacca*)
- *Haridra* (*Curcuma longa*)
- *Daruharidra* (*Berberisaristata*)
- Honey
- Base and other Emulsificants

Pharmaceutical study-

.The modified form of *Manashiladi Lepa* in ointment form was prepared under standardized condition in trial batch initially and later in 6 batches for standardization.

Method of preparation:

- All the drugs listed were taken in equal quantity.
- *Manashila* is purified by subjecting it to *Bhavana* with *Ardraka Swarasa* for 7 times[5].
- The fine powder of purified *Manashila* is kept ready by powdering it in a pestle.
- The coarse powder of the herbal drugs of *Manjishta*, *Ela*, *Haridra* and *Daruharidra* is kept ready.
- The coarse powders of the herbs are subjected to extraction using Soxhlet apparatus.

- The powder of *Laksha* is melted and added to the extract of the herbs along with other ingredients. Honey is also added at this stage.
- All the ingredients are mixed together in a beaker and added with emulsifying fat (carbopol 4%), liquid paraffin and white soft paraffin.
- Preservative (0.1% Methylparaben & Propylparaben) was dissolved in a mixture of water and propylene glycol.
- It is then subjected to proper mixture by continuous stirring and made into ointment
- The prepared ointment is packed into the containers.

Analytical study:

Ointments are semi-solid preparations meant for external application to the skin or mucous membrane[6].The prepared sample was subjected for analytical study and the readings were found as shown in table number 1.

Table no. 1 : Analytical study readings.

S. I. No.	Test
1	Loss on drying- 0.085%
2	Refractive index- 1.733
3	Saponification value- 189.68
4	Acid Value- 3.877
5	Spreadability test- 23.07 gm-cm/sec
6	Viscosity- 73810

7	Specific gravity (at 30 ⁰ C)- 0.7538
8	Unsaponification value- 75.8
9	Ester value- 107.330
10	Free fatty acid- 56.6
11	pH- 7.25
12	TLC Rf value at 0.328, 0.556, 0.713

Microbial contamination Formulation were evaluated for total bacterial count and total fungal count. The test revealed that the sample was free from bacterial and fungal contamination . Total aerobic microbial count was carried out by plate count method.

Topical sensitivity test

This is done to check any possibilities of developing skin irritation or other adverse reaction by topical application of the formulation. Ointment was applied to the elbow of the hand and observed for any side effects like skin inflammation, irritation, reddening of skin (allergic reaction) etc.

Clinical Study

Study design- Randomized Control Clinical Trial

Study population- Post- surgical patients who have undergone caesarian section in Alvas health centre..

Sampling method- Simple Random Sampling.

IEC Approval Letter Number- ICEC / RGUHS/06

CTRI Registration Number- CTRI/2017/03/008147

Study setting- Post- surgical patients, who have undergone caesarian section from January 2019 to March 2020 in Alva's health centre moodbidiri were studied.

Study size- 100 patients. 50patients in group-A (Control) and 50 patients in group-B (Trial drug group)

Sample and data source

A total of 100 post- surgical patients who have undergone caesarian section in Alva's health centre moodbidiri were studied.

Criteria of selection

Post- surgical patients who have undergone caesarian section were selected.

Criteria of exclusion

Patients with systemic diseases like diabetes, tuberculosis etc.

Methods

Group A patients were observed without application of any ointment.

For trial Group B, trial drug- *Manashiladi* ointment was applied

Procedure of *Lepa*:

Thickness - 2mm

Frequency Of Application- Thrice a day over the sutured area (morning, noon, evening)

Duration of application - 20 minutes.

Duration of treatment- 21 days

After 21 days the patients were assessed for the presence or absence of scar marks over the sutured area.

Criteria for assessment

The patients were assessed on subjective and objective parameter on the basis of the score adopted with grading (0, 1, 2 and 3.)

Subjective -Pain, Itching, Odema, Infection, Rise in local temperature, Discharge.

Objective parameters-Thickness (in mm),Width(in mm),Shape of Scar(Liner line or Boat), Color(brownish or Grayish ,Skin).

After completion of treatment, assessment of scar was done on the basis of observations like Complete Absence of Scar , Partial Disappearance of Scar , No Change in scar and Days taken for Wound Healing.

Statistical analysis:the results are drawn after analyzing the findings statistically by Wilcoxon Signed Rank Test and Mann-Whitney Rank Test.

OBSERVATIONS AND RESULTS

The study carried on females who underwent Caesarian section majority of them were found in the age group of 21-30 years (68) , 31 to 40 years 17 and in 41 to 50 years 01 patient is observed . All the patients were found to be non addicted. Majority of them were found to be following mixed diet.67 patients were belongs to Hindu community, Muslim 21 and Christian 6. Among patients 76 patients were belongs to middle class, 15 were belongs to upper middle class and 9 patients were from lower middle class. 42 patients were belongs to *Pittakapha Prakriti*. In relation Hb level most of them were found to be

ranging from 12 to 13.9. Regular shape of the wound was observed in all cases. Cases studied were having the average wound length of 12 cm, depth of 2 cm and width of 3cm. On first day of study patients were showing mild edematous margin and having mild discharge. The chief complaints were pain and tenderness, found in the patients. Subjective criteria like pain, edema, infection, itching, discharge & local temperatures did not showed any significant differences between the groups. Their average days taken for

wound healing in group B was 7 and in group A was 11.

Overall effect of therapy on scar formation

Scar size was observed to be minimal in group B in comparison to group A. In relation to width, days taken for wound healing and thickness significant differences observed in the test & control groups. Colour, Shape, discharge, edema, infection and local temperature did not had any significant differences in between the groups. In Group B partial disappearance of scar were observed were as scar present in Group A.

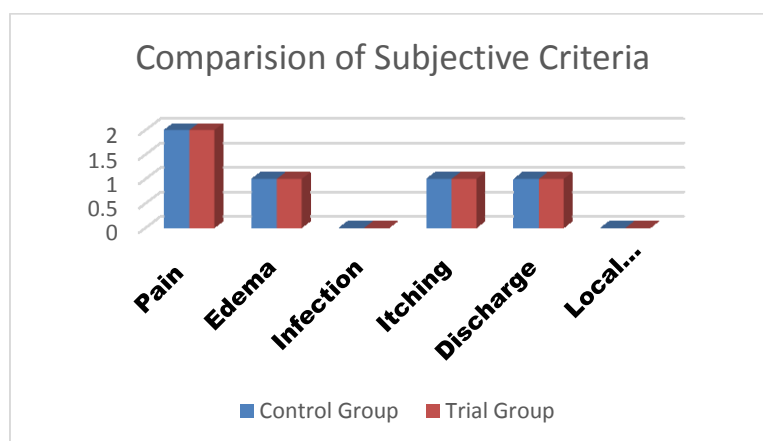


Figure no. 1: Comparison of subjective criteria

Table no. 2 : Days required for wound healing.

Column	Size	Missing	Mean	StdDev	Std. Error	C.I. of Mean
# Days-CTRL	50	0	12.440	0.733	0.104	0.208
# Days - Trial	50	0	6.120	1.745	0.247	0.496

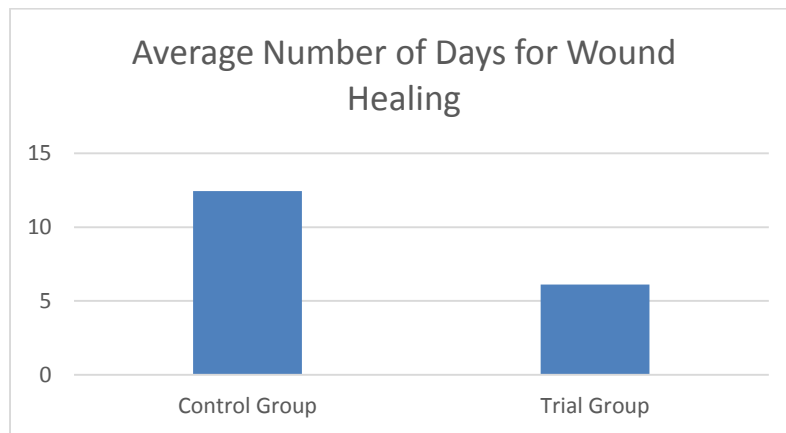


Figure no.2 : Average days for wound healing

Mann-Whitney U Statistic= 0.000
 T = 3775.000 n(small)= 50 n(big)= 50 (P = <0.001)

The difference in the median values between the two groups is greater than would be expected by chance; there is a statistically significant difference (P = <0.001)

Table no. 3 :Width of wound

Group	N	Missing	Median	25%	75%
Width-CTRL	50	0	0.000	0.000	0.000
Width-Trial	50	0	-1.000	-1.000	-1.000

Mann-Whitney U Statistic= 0.000
 T = 3775.000 n(small)= 50 n(big)= 50 (P = <0.001)

The difference in the median values between the two groups is greater than would be expected by chance; there is a statistically significant difference (P = <0.001)

Table no.4 : Thickness of wound

Group	N	Missing	Median	25%	75%
Thickness -CTRL	50	0	0.000	0.000	0.000
Thickness -Trial	50	0	-1.000	-1.000	-1.000

Mann-Whitney U Statistic= 0.000
 T = 3775.000 n(small)= 50 n(big)= 50 (P = <0.001)

The difference in the median values between the two groups is greater than would be

expected by chance; there is a statistically significant difference (P = <0.001)

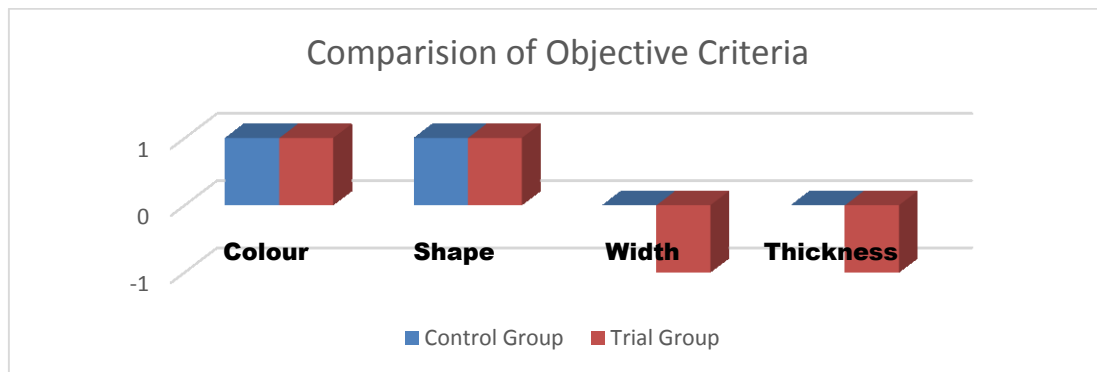


Figure no. 3 : Comparison of objective criteria.

DISCUSSION

Pharmaceutical study

Manashiladi Lepa is a formulation, which is to be used for external application to prevent the formation of scars. The formulation contains ghee as an additive to other ingredients, which is to be added just before the application over the skin. Since this causes practical difficulty to patients, the formulation needed to be modified. Hence it was modified into ointment so that it is easy for packing, improve shelf life and convenience of usage by patients.

All the ingredients were taken in equal quantity as told in the reference. The preparation of the initial batch of ointment is a trial and error method as it involves finding the right combination of the different bases available. The success of the product depends upon the consistency of the final product, the type of ointment i.e. water in water, oil in water etc. Purified *manashila* should be

powdered to a very fine form and filtered using a fine mesh before adding into the preparation. Otherwise rough particles of the powdered *manashila* may damage the skin during the application. Since the drug is poisonous, proper *shodhana* is to be done before using it for therapeutic use. Honey is added at the last after addition of purified *manashila*, so that the consistency of the ointment is maintained properly. The ointment is prepared on the same day that the extract of the herbal ingredients are prepared so as to get the right consistency of the final product. The stirring of the preparation is to be done by a glass rod continuously in order to get the perfect consistency of the product. Avoid the formation of lumps, hard granules during the preparation of the ointment. The color of the preparation changed from dark red to slight pale red during the entire process

Analytical study

There are no readings set by the government agencies for the formulation of this study to be compared. The loss on drying is only 0.085%, it indicates that the moisture content is minimal and help in maintaining the shelf life of the product. The refractive index 1.733 is indicative of fewer impurities. Saponification value of 189.68 is an indicator of good shelf life of the prepared sample[7]. The lesser the acid value of a formulation, the better is its shelf life. The spreadability value of 23.07gm-cm/sec is a good indicator of its thickness and indicates that it will hold to the skin surface during application and run off from the surface. The formulation has desirable viscosity value of 73810 and spreadability so that it is retained over the skin and absorbed quickly. Specific gravity less than 1 indicates that the formulation is lighter than water and it will not leave a residue or oiliness in the skin after application. The unsaponification value of 75.8 is a good indicator of the ointment being good for moisturizing to the skin after application. The ester value of 107.330 in the formulation is an indicator that it helps in improving the texture of the skin, which is needed as per the study. The low free fatty acid value of 56.6 indicates that the prepared sample is having good shelf life and less chances of rancidity in short term of 6 months to 1 year. The pH value of 7.25 indicates that

the prepared sample is close to neutral in nature and will not harm the skin on application. Microbial contamination test revealed that the sample was free from bacterial and fungal contamination indicating it can be used safely in therapeutics. Topical sensitivity test results proved it is non – irritating to skin

Clinical study

Study mainly carried out in cesarean wound as the ladies are much worried about scar formation after cesarean section. They are beauty conscious and also it is easy to convince them for the study. Wound healing is completed in three phases: Inflammatory, proliferative and remodeling. Granulation, collagen maturation and scar formation are some of the other phases of wound healing [8]. In *Ayurveda* proper wound healing depends on two concepts *Ropana* and *shodhana*, because a wound cannot be healed if it is *Ashuddha*. Prevention of scar formation mainly depends on proper wound healing, it may be considered as *Vaikrutapaha Chikitsa*. Hence, the modified *Manashilaadi Lepa*, which is mainly indicated in prevention of scar and having the *Shodhana*, *Ropana* and *Lekhana* properties had been selected for this study. An attempt was made to explore properties of the trial drug scientifically. *Vranaropana* involves *Shodhana*

followed by *Ropana*; two stages happen practically, i.e., subsiding local *Shotha* by removal of local *Dhatu Dushti*, followed by initiation of *Ropana* process, i.e., contraction and covering of wound by epithelial layers.

The grading of *Shuddha* wound depends on the amount of *Dushti* present in local *Dhatu*, i.e., *Twak and Mamsa with Rakta Dhatu*. The statistical analysis between 2 groups revealed that significant results were obtained in wound healing, width, thickness and it is insignificant in relation to color, shape, edema, discharge, infection, local temperature. Average number of days required for wound healing was lesser in group B as compared to group A. This indicates that the ointment was effective in wound healing. All the treated wounds showed secondary healing within a range of 21 days, with a lighter, minimal and smooth scar formation without any complications in Group B, whereas Group A patients showed little larger, darker and firmer scar formation. The ingredients of trial drug mainly having the properties

Lekhana (scraping), *Shoshana* (absorptive) *Sthambhana* (coagulation/contraction) *Varnya*, *Sandhanakara* and *Rakta Shodhaka* (blood purifier) properties, along with *Samshodhana* and *Visha Ahara* (detoxifying, cleansing) which provided the desired effect. The *Ropana* of *Vrana* (wound) could have

been possible after *Shodhana* (medical debridement) due to removal of *Dhatu Dushti* with the help of *Yogavahi* (catalytic) properties of honey. *Yogavahi* (catalytic) properties of honey which removed and clean *Dhatu Dushti* as well as carried out the *Shodhana* (medical debridement) at the site of *Vrana* would have been acted and promoted the *ropana* of *vrana* (wound).

Effect on the clinical features

Ropana (healing) of any *vrana* (wound) cannot occur without the reduction of the clinical features of *shotha* (inflammation). Though it is necessary for *Ropana* (healing) of *Vrana* at early stages, it delays the healing if persists for a longer duration.

The *Rasa*, *Guna*(s) and *Karma*(s) of the trial drug helped to prevent scar formation. *Prinana* (nutrition), *Dhatuwardhana* (tissue growth) *Poshana* (nourishment)-all activities must be performed by *Madhura* rasa and it helps to contract the wound size by promoting fibrosis and epithelialization. *Vatahara* due to *Snigdha* and *Guru* *Guna*, *Shothahara* and *Dahashamana* (anti-inflammatory) effects was observed due to *Sheeta* *Guna* and *Kashaya* *Rasa* which helped to reduce the inflammation and thus relieved the pain and tenderness. *Raktashodhana* (purification of blood) was done by virtue of *Tikta* and *Kashaya* *Rasa*. *Pittashamana*,

Varnya (coloration) and *Twak Prasadana* (to make skin healthy) actions aided to improve the skin color by improving the local blood circulation. *Stambhana karma* was done by *Shoshana Guna* of *Kashaya*, *Tikta Rasa* and a *Vishada Guna* along with *Kledahara*, *Raktastambhana* and *Chhedana* activities, followed by *Krimighna Karma* (antimicrobial action) which led to prevention of discharge and secretions. *Lekhana*, *Kledahara*, *Chhedana* and *Raktashodhaka* properties of *Vishada Guna* of *kashaya rasa* played important role in scraping out the debris and slough of the *Vrana*. Infection was checked by the *Krimighna* and *Vishaghna* properties of the *Haridra* of the compound drug. Ultimately, normal scar tissue was observed with minimal size, near to normal skin color, smooth, even and regular surface with normal consistency. *Balya* and *Poshana Karma* of *Madhura Rasa* helped in promotion of healing by *Dhatuwardhana* (growth of the tissue) leading to healthy and desired scar formation. *Varnya*, *Twak Prasadana*, *Raktaprasadana* properties of the *Madhura Rasa* with *Snigdha Guna* led to coloration of scar tissue similar to that of skin. *Snigdha* and *Balya* properties of *Madhura Rasa* of the individual drugs normal, even and smooth scar. Qualities of *KashayaRasa*[9], *Snigdha* and *Laghu Guna* of

the drug led to even and regular consistency of scar formation without any complications. Palmitine and berberines both have bactericidal action and glycosides have anti-infective activity which combated the infection and thus prevented infections in the wound. Tannins, anthraquinones, berberine, and phytosterols – all are anti-inflammatory and thus prevented the prolongation of the initial phase and reduced the pain as well as tenderness, redness, swelling like features, which led to progress of the wound toward healing. Tannins and phytosterols promoted the healing process by wound contraction with increased capillary formation and fibroblast proliferation, followed by enhanced rate of epithelialization. Glycosides accelerated the healing process and reduced the scarring, as the proposed mechanism of action involves the regeneration of skin through stimulation of stem cells that allowed healing without substantial scar formation. Ascorbic acid is an important requirement for collagen connective tissue synthesis which leads to wound contraction and scar maturation by cross-linking of collagen fibers. Vitamin “A” is essential for epithelialization which lessens the pigmentation and improves the condition of the scar [10], it can be assumed that the drug was able to prevent any such conditions of infection and thus helped in preventing the scar formation.

CONCLUSION

In the preparation of ointment form *Manashiladi Lepa*, it is seen that the modification is needed in the present time to improve the shelf life of the product, easy packing and better acceptability by the patients. The ointment has undergone various analytical tests to justify its modification and show that it can replace the original *Lepa* form in the present era. By the clinical study findings we can say that, dermal application of ointment form did not have any side effects and it could consequently be used as an adjunctive treatment to the standard treatments of cesarean wound, the process of repair was not complicated by infection with micro-organisms. So, there was no interference with the general health of the patient [11]. It is observed that scar formation is happened within 21 days with good results in the form of normal colored scar formation without any complication in the trial group, which proved the *Vaikritapaham* property. Local application of ointment provided good result by reduction of the wound size and promotion of healing, and it proved to be cosmetically effective by partially preventing scar formation. Pigmentation nearer to that of skin was found as another updating effect which was least in control group. Hence, from this clinical study, it can be concluded that the

drug *Manashilaadi Ointment* shown encouraging result in preventing scar formation with fine scaring without producing any adverse effect. So, it can be recommended as a cost-effective, easy to prepare and partially effective in preventing the scar formation in post surgical cases.

ACKNOWLEDGEMENT-

The author is highly thankful to the Directorate of Research wing of Rajiv Gandhi University of Health sciences, Bengaluru for providing the financial assistance to carry out the research on the title- 'Clinical Evaluation of Modified ManashiladiLepa in the prevention of post- surgical scar '.

REFERENCES:

1. Acharya RadhakrishnaParashara(editor). SharangadharaSamhita of Sharangadhara; madhyamakhandha ;4th edition, Nagpur : Sri Baidyanath Ayurveda Bhavan Ltd publication;1994; 536.
2. Rasatantrasaravasiddhaprayogasamgraha Part 1; 25th edition, Krishnagopal Ayurveda Bhavanpublication;Ajmeer ; 2010; 437.
3. Clark RA, Goldsmith LA (editor. Physiology, Biochemistry and Molecular Biology of Skin). Cutaneous wound repairs. New York: Oxford University Press publication; 1991; 576.
4. Kiritikar K.R &Basu B.D. Indian Medicinal Plants Vol.1; 2nd edition, International Book New Delhi : Distributors publication; 1987; 688.
5. Pt. ShastriKashinath. Rasatarangini; 11th edition, Varanasi: MotilalBanarasidas publication; 2004; 262
6. Mehta R M. Dispensing Pharmacy; 4th edition, New Delhi :VallabhPrakashan publication; 2012; 230

7. Ayurvedic Formulary of India, Govt. of India, Ministry of Health and Family planning, Dept. of Health, New Delhi, 1st Vol. 1st edition, 1978.
8. Townsend CM, Beauchamp DR, Evers MB, Mattox KL. Sabiston's Textbook of Surgery;17th edition, Amsterdam: Elseviers Saunders publication; 2004;1–15
9. Pandey GS, Mishra Prakarana (editors). commentary by ChunekarKCMargaret. BhavaprakashNighantu of Bhavamishra. Varanasi: ChaukhambhaBharati Academy; 2004:187
10. Farquharson and Brendan Moran. Farquarson's Textbook of Operative General Surgery; 9th edition, London: Hodder Arnold publication; 2005; 439
11. Alexis Thompson and Alexander Miles. Manual of Surgery Vol. 1; 6th edition, Oxford: Oxford Medical Publications; 1990;14

Cite this article as:

Suresh Y, Prashanth BK, Ravi Rao, Prashanth Kekuda. Clinical Evaluation of Modified ManashiladiLepa in the prevention of post- surgical scar. *J of Ayurveda and Hol Med (JAHM)*.2020; 8(3):1-13

Source of support: Nil

Conflict of interest: None Declared